Management of Complications in Refractive Surgery

Second Edition

Jorge L. Alio
Dimitri T. Azar
Editors

Springer

Management of Complications in Refractive Surgery

Jorge L. Alio • Dimitri T. Azar
Editors

Management of Complications in Refractive Surgery

Second Edition

Springer

Editors
Jorge L. Alio
Department of Ophthalmology
Miguel Hernandez University
Alicante, Spain

Dimitri T. Azar
Department of Ophthalmologic Research
University of Illinois at Chicago
Chicago, IL
USA

Verily Life Sciences
Alphabet, SF, CA
USA

ISBN 978-3-319-60560-9 ISBN 978-3-319-60561-6 (eBook)
https://doi.org/10.1007/978-3-319-60561-6

Library of Congress Control Number: 2017955692

Printed on acid-free paper

This Springer imprint is published by Springer Nature
The registered company is Springer International Publishing AG
The registered company address is: Gewerbestrasse 11, 6330 Cham, Switzerland

Acknowledgements

Special thanks to Jorge Alio del Barrio and Joelle Hallak.

List of Associate Editors

Contents

List of Contributors

Ahmed A. Abdelghany, M.D., Ph.D. Ophthalmology Department, Faculty of Medicine, Minia University, Minia, Egypt

Natalie A. Afshari Shiley Eye Institute, University of California, San Diego, CA, USA

Jorge L. Alio, M.D., Ph.D., F.E.B.O. Vissum Corporation-Instituto Oftalmológico de Alicante, Alicante, Spain

Department of Ophthalmology, Universidad Miguel Hernández, Alicante, Spain

Jorge L. Alio del Barrio, M.D., Ph.D. Cornea, Refractive and Cataract Surgery Unit, Vissum/Instituto Oftalmológico de Alicante, Alicante, Spain

Department of Ophthalmology, Universidad Miguel Hernández, Alicante, Spain

Norma Allemann, M.D. Department of Ophthalmology, Paulista School of Medicine, Federal University of São Paulo, São Paulo, Brazil

Noel Alpins, AM., FRAZCO., FRC.Ophth, FACS. Department Ophthalmology, Melbourne University, Cheltenham, VIC, Australia

Renato Ambrósio Jr, M.D., Ph.D. Instituto de Olhos Renato Ambrósio, Visare Personal Laser & Refracta-RIO, Rio de Janeiro, Brazil

Department of Ophthalmology, Federal University of São Paulo—"Escola Paulista de Medicina", São Paulo, Brazil

U. Andrea Arteaga Department of Ophthalmology and Visual Sciences, University of Illinois at Chicago, Chicago, IL, USA

Konstantinos Andreanos, M.D. Department of Ophthalmology, G. Gennimatas General Hospital, University of Athens, Athens, Greece

Fernando A. Arevalo, B.S. Retina and Vitreous Service, Clinica Oftalmologica Centro Caracas, Caracas, Venezuela

J. Fernando Arevalo, M.D., F.A.C.S. Retina Division, Wilmer Eye Institute, Johns Hopkins University School of Medicine, Baltimore, MD, USA

Jean Louis Arne, M.D. University of Toulouse, Toulouse, France

Dimitri T. Azar Department of Ophthalmology and Visual Sciences, University of Illinois at Chicago, Chicago, IL, USA

College of Medicine, University of Illinois, Chicago, IL, USA

Michael W. Belin Department of Ophthalmology and Vision Science, The University of Arizona, Tucson, AZ, USA

Sina Bidgoli Vissum Corporation-Instituto Oftalmológico de Alicante, Alicante, Spain

Roberto Fernández Buenaga, M.D., Ph.D. Vissum Madrid, Madrid, Spain

Claudia Castell, M.D. Bogota Laser Ocular Surgery Center, Bogota, Colombia

Wallace Chamon, M.D. Department of Ophthalmology, Paulista School of Medicine, Federal University of São Paulo, São Paulo, Brazil

Arturo S. Chayet Codet Vision Institute, Tijuana, Mexico

Béatrice Cochener, M.D. University of Brest, Brest, France

Jose de la Cruz, M.D. Department of Ophthalmology and Visual Sciences, University of Illinois at Chicago, Chicago, IL, USA

Pan-American Cornea Society, University of Illinois at Chicago, Chicago, IL, USA

Konstantinos Droutsas, M.D., Ph.D. Department of Ophthalmology, G. Gennimatas General Hospital, University of Athens, Athens, Greece

Daniel Elies, M.D. Cornea and refractive Surgery Unit, Instituto de Microcirugia Ocular (IMO), Barcelona, Spain

David Fahd Cornea, Cataract, and Refractive Surgery, Kesrwan Medical Center, Metn, Lebanon

Fernando Faria-Correia, M.D. Rio de Janeiro Corneal Tomography and Biomechanics Study Group, Rio de Janeiro, Brazil

Life and Health Sciences Research Institute (ICVS), School of Health Sciences, University of Minho, Braga, Portugal

Marta S. Figueroa, M.D., Ph.D. Department of Retina and Vitreous, Vissum Madrid, Madrid, Spain

Department of Ophthalmology, Ramón y Cajal University Hospital, Madrid, Spain

University of Alcalá de Henares, Madrid, Spain

Veronica Vargas Fragoso Vissum Corporation, Alicante, Spain

Jose L. Güell, M.D., Ph.D. Cornea and Refractive Surgery Unit, Instituto de Microcirugia Ocular (IMO), Barcelona, Spain

Eric E. Gabison, M.D. Department of Ophthalmology, Fondation Ophtalmologique A. de Rothschild and Bichat Hospital, Paris, France

CNRS UMR 7149, University Paris XII, Paris, France

Reinaldo A. Garcia, M.D. Clínica Oftalmológica El Viñedo, Valencia, Venezuela

Javier Gaytan, M.D. Cornea, Cirugia Refractive y seg. Anterior, Hospital Angeles Puebla, Puebla, Mexico

Ramon C. Ghanem Sadalla Amin Ghanem Eye Hospital, Joinville, SC, Brazil

Vinicius C. Ghanem Sadalla Amin Ghanem Eye Hospital, Joinville, SC, Brazil

Almutez M. Gharaibeh, M.D. Faculty of Medicine, The University of Jordan, Amman, Jordan

Andrea Govetto, M.D. Department of Ophthalmology, Ramón y Cajal University Hospital, Madrid, Spain

Retina Division, Stein Eye Institute, University of California Los Angeles, Los Angeles, CA, USA

Enrique O. Graue-Hernández, M.D., M.Sc Cornea and Refractive Surgery, Instituto de Oftalmología Fundación Conde de Valenciana, Mexico City, Mexico

Universidad Nacional Autónoma de Mexico, Mexico City, Mexico

Oscar Gris, M.D., Ph.D. Cornea and refractive Surgery Unit, Instituto de Microcirugia Ocular (IMO), Barcelona, Spain

Joelle Hallak Department of Ophthalmology and Visual Sciences, University of Illinois at Chicago, Chicago, IL, USA

Department of Ophthalmology and Visual Sciences, Ophthalmic Clinical Trials and Translational Center, University of Illinois at Chicago, Chicago, IL, USA

Ramon Hallal Rio de Janeiro Corneal Tomography and Biomechanics Study Group, Rio de Janeiro, Brazil

Department of Ophthalmology, Hospital Federal da Lagoa, Rio de Janeiro, Brazil

Sadeer B. Hannush Department of Ophthalmology, Wills Eye Hospital, Philadelphia, PA, USA

Jefferson Medical College of Thomas Jefferson University, Philadelphia, PA, USA

David R. Hardten, M.D. Minnesota Eye Consultants, Minnetonka, MN, USA

Department of Ophthalmology, University of Minnesota, Minneapolis, MN, USA

Adeline G. Hardten Minnesota Eye Consultants, Minnetonka, MN, USA

Department of Ophthalmology, University of Minnesota, Minneapolis, MN, USA

Sophia A. Hardten Minnesota Eye Consultants, Minnetonka, MN, USA

Department of Ophthalmology, University of Minnesota, Minneapolis, MN, USA

Teresa S. Ignacio IntraLase Corp., Irvine, CA, USA

Sandeep Jain, M.D. Department of Ophthalmology and Visual Sciences, University of Illinois at Chicago, Chicago, IL, USA

Department of Ophthalmology, Cornea Service, Chicago, IL, USA

Translational Biology Laboratory, University of Illinois at Chicago, Chicago, IL, USA

Dry Eye Service and oGVHD Service, University of Illinois at Chicago, Chicago, IL, USA

Advaite, LLC, Chicago, IL, USA

Investigative Ophthalmology and Visual Sciences, Ocular Surface, Chicago, IL, USA

Soraya M.R. Jonker, M.D. University Eye Clinic Maastricht, Maastricht University Medical Center, Maastricht, The Netherlands

Vikentia J. Katsanevaki, M.D., Ph.D. University of Crete, Crete, Greece

Andreas Katsanos, M.D. Universidad de Alcalá Madrid, Madrid, Spain

Clínica Novovision de Madrid, Madrid, Spain

Bhairavi Kharod-Dholakia Cornea and Refractive Surgery, Emory Eye Center, Atlanta, GA, USA

George Kymionis, M.D., Ph.D. Department of Ophthalmology, G. Gennimatas General Hospital, University of Athens, Athens, Greece

Richard L. Lindstrom, M.D. Minnesota Eye Consultants, Minnetonka, MN, USA

University of Minnesota, Minneapolis, MN, USA

Javier Lopez Codet Vision Institute, Tijuana, Mexico

Carlo F. Lovisolo, M.D. Quattroelle Eye Centers, Milan, Italy

Felicidad Manero, M.D. Cornea and Refractive Surgery Unit, Instituto de Microcirugia Ocular (IMO), Barcelona, Spain

Antonio A.P. Marinho, M.D., Ph.D. Hospital Arrábida, Porto, Portugal

Merce Morral, M.D., Ph.D. Cornea and Refractive Surgery Unit, Instituto de Microcirugia Ocular (IMO), Barcelona, Spain

Andreas Mouchtouris, M.D. Department of Ophthalmology, G. Gennimatas General Hospital, University of Athens, Athens, Greece

Rudy M.M.A. Nuijts, M.D., Ph.D. University Eye Clinic Maastricht, Maastricht University Medical Center, Maastricht, The Netherlands

M. Emilia Mulet, M.D., Ph.D. Department of Ophthalmology, Miguel Hernández University, Alicante, Spain

Department of Research and Development, Vissum Instituto Oftalmologico de Alicante, Alicante, Spain

David P.S. O'Brart, M.D., F.R.C.S, F.R.C.Ophth, D.O. King's College, London, UK

Guy's and St. Thomas' NHS Foundation Trust, London, UK

Konstantinos Oikonomakis, M.D. Department of Ophthalmology, G. Gennimatas General Hospital, University of Athens, Athens, Greece

Renan F. Oliveira Sadalla Amin Ghanem Eye Hospital, Joinville, SC, Brazil

Konrad Pesudovs, Ph.D. NH&MRC Centre for Clinical Eye Research, Department of Optometry, Flinders University, Adelaide, SA, Australia

Isaac Ramos, M.D. Rio de Janeiro Corneal Tomography and Biomechanics Study Group, Rio de Janeiro, Brazil

Jerome C. Ramos-Esteban Department of Ophthalmology, General Boynton Beach, Boynton Beach, FL, USA

J. Bradley Randleman, M.D. Roski Eye Institute, University of Southern California, Los Angeles, CA, USA

Department of Ophthalmology, Keck School of Medicine of the University of Southern California, Los Angeles, CA, USA

Antonio Renna, M.D. Vissum, Instituto Oftalmológico Alicante, Alicante, Spain

Department of Medical and Biological Sciences—Ophthalmology, University of Udine, Udine, Italy

Emanuel Rosen, M.D., F.R.C.S.Ed. Private Practice, Manchester, UK

Julie M. Schallhorn, M.D., M.S. Roski Eye Institute, University of Southern California, Los Angeles, CA, USA

Department of Ophthalmology, Keck School of Medicine of the University of Southern California, Los Angeles, CA, USA

Juan Carlos Serna-Ojeda, M.D. Instituto de Oftalmología Fundación Conde de Valenciana Mexico City, Mexico City, Mexico

Pete Setabur Department of Ophthalmology and Visual Sciences, University of Illinois, Champaign, IL, USA

Bryan Sires Allure Facial Laser Center, University of Washington, Kirkland, WA, USA

Stephen G. Slade, M.D., F.A.C.S. Slade & Baker Vision, Houston, TX, USA

Felipe Soria, M.D. Instituto de la Vision-Hospital La Carlota, Universidad de Montemorelos, Montemorelos, Mexico

George Stamatelatos, B.Sc.Optom NewVision Clinics, Melbourne, VIC, Australia

Roger F. Steinert, M.D. Department of Ophthalmology, University of California, Irvine, CA, USA

Karl G. Stonecipher The University of North Carolina at Chapel Hill, Chapel Hill, NC, USA

R. Doyle Stulting, M.D., Ph.D. Stulting Research Center at Woolfson Eye Institute, Atlanta, GA, USA

Nayyirih G. Tahzib, M.D., Ph.D. University Eye Clinic Maastricht, Maastricht University Medical Center, Maastricht, The Netherlands

Jonathan H. Talamo Johnson & Johnson Vision Care, Inc., Jacksonville, FL, USA

Gustavo Tamayo, M.D. Bogota Laser Ocular Surgery Center, Bogota, Colombia

Miguel A. Teus Universidad de Alcalá Madrid, Madrid, Spain
Clínica Novovision de Madrid, Madrid, Spain

Mauro Tiveron Jr., M.D. Vissum, Instituto Oftalmológico Alicante, Alicante, Spain
Universidad Miguel Hernandez, Alicante, Spain

Luis F. Torres Innova Vision, Aguascalientes, Mexico

Andre A.M. Torricelli Department of Ophthalmology, Hospital das Clinicas HCFMUSP, Faculdade de Medicina, Universidade de Sao Paulo, Sao Paulo, Brazil

Pilar Vargas, M.D. Bogota Laser Ocular Surgery Center, Bogota, Colombia

Alfredo Vega-Estrada, M.D., Ph.D. Department of Cornea and Refractive Surgery, Vissum Alicante, Alicante, Spain
Keratoconus Unit, Vissum Alicante, Alicante, Spain
Division of Ophthalmology, Universidad Miguel Hernández, Alicante, Spain

O. Bennett Walton, M.D., M.B.A Slade & Baker Vision, Houston, TX, USA

Steven E. Wilson Department of Ophthalmology, Cole Eye Institute, The Cleveland Clinic, Cleveland, OH, USA

Roger Zaldivar, M.D. Instituto Zaldivar, Mendoza, Argentina

Alice Yang Zhang, M.D. Retina Division, Wilmer Eye Institute, Johns Hopkins University School of Medicine, Baltimore, MD, USA

Part I

Overview

1 Refractive Surgery Outcomes and Frequency of Complications

Wallace Chamon, Norma Allemann, Jorge L. Alio, and Ahmed A. Abdelghany

Core Messages

- In refractive surgery, there is no risk-free surgical procedure. The evaluation of the risk/benefit ratio should be part of a continuous process of patient care.
- Refractive surgery risks and benefits should be evaluated individually in order to choose the surgical approach properly.
- Disease distribution of each possible complication should be considered.
- Decision-making in refractive procedure is an individualized process that should be based on scientific knowledge, patient's characteristics, and surgeon experience.
- The informed consent should reflect all risks/benefits clearly to the patient candidate for any refractive surgery procedure.

1.1 Introduction

Refractive surgical procedures are generally divided into additive procedures, with implantation of phakic intraocular lens (IOL), and subtractive procedures, with ablation of the corneal tissue [1].

W. Chamon, M.D. • N. Allemann, M.D.
Department of Ophthalmology, Paulista School of Medicine, Federal University of São Paulo, São Paulo, Brazil

J.L. Alio, M.D., Ph.D., F.E.B.O. (✉)
Vissum Corporación, Avda de Denia s/n, Edificio Vissum, Alicante 03016, Spain

Division of Ophthalmology, Universidad Miguel Hernández, Alicante, Spain
e-mail: jlalio@vissum.com

A.A. Abdelghany, M.D., Ph.D.
Ophthalmology Department, Faculty of Medicine, Minia University, Minia, Egypt

In 2004, the European Society of Cataract and Refractive Surgeons (ESCRS) took the initiative to establish a registry for refractive surgery outcomes: the Refractive Surgery Outcomes Information System (RSOIS). The purpose of this web-based system was to record outcomes of refractive surgery and improve quality of care for these procedures. Reasons behind the initiative were the growing health in truest within the field and increasing patient complaints after refractive surgery reported in the press, in some countries [2, 3]. Patient complaints were thought to be associated with inappropriate indications and surgery outside the limits of the procedure, leading to suboptimal outcomes in refractive surgery.

In refractive surgery, the goal is to achieve optimal visual acuity, optimal refraction (usually emmetropia), and no complications [4]. Complications during and after surgery are of distinct concern as the eyes undergoing refractive surgery are usually healthy eyes.

In this chapter, we are going to discuss refractive surgery outcomes and complications in each group of refractive surgical procedures.

1.2 Laser Refractive Surgery

Laser refractive surgery is one of the most commonly performed eye surgeries worldwide and has been established to be successful in correcting refractive errors [5].

Several benchmarks have been established for laser keratorefractive surgery. The Food and Drug Administration (FDA) based on data presented by several evidence-based reviews defined the correction limitation of excimer laser (Table 1.1) [6].

The American Academy of Ophthalmologist (AAO) reports stated that the substantial level II and III evidence proved that excimer laser refractive surgery, whether laser in situ keratomileusis (LASIK) or photorefractive keratectomy (PRK), is a safe and effective tool of correcting the full

J.L. Alio, D.T. Azar (eds.), *Management of Complications in Refractive Surgery*,
https://doi.org/10.1007/978-3-319-60561-6_1

Table 1.1 FDA indications for LASIK and PRK [6]

	LASIK	PRK
Myopia	Less than −14.0 D with or without astigmatism between −50 and −5.00 D	Up to −12.0 D with or without astigmatism up to −4.00 D
Hyperopia	Up to +5.00 D with or without astigmatism up to +3.00 D	Up to +5.00 D with or without astigmatism up to +4.00 D
Mixed astigmatism	Astigmatism up to 6.00 D, the cylinder is greater than the sphere and of opposite sign	

spectrum of refractive errors but with some limitations in high hyperopic refractive errors [6, 7].

The latest generation of excimer laser platforms had introduced a large number of features such as faster laser, smaller spot size, a high speed tracker, pupil monitoring, and online pachymetry, all of which provided superior treatment with significant improvement of induced postoperative high-order aberrations (HOA) and control of thermal damage [8].

With the advent of keratomileusis procedures, primarily LASIK, a new anatomic region in the cornea came into existence: the potential space between anterior and posterior corneal lamellae commonly referred to as the LASIK interface. Within this region, a number of biochemical processes occur after creation of the corneal flap, including limited wound healing and intercellular reorganization [9]. The anatomy of the LASIK interface allows for a variety of potential unique complications to arise from different etiologies with often overlapping clinical presentations.

1.2.1 Common Complications Associated with Laser Refractive Surgery

1.2.1.1 Refractive Imprecision and Loss of Spectacle-Corrected Visual Acuity

The most frequent complication observed in any refractive procedure is the lack in achieving accurate refractive outcome. As a general rule, accuracy decreases with the amount of refractive error. Photoablative procedures tend to be the most accurate ones for low ametropias. PRK and LASIK deal with different variables that may affect predictability, such as corneal wound healing and stromal bed elasticity, respectively [10].

We may expect that in any photoablative procedure, approximately 60–70% of eyes will achieve 20/20 uncorrected visual acuity and will be within +/−0.50 D after surgery. If we analyze only low myopias (under 6.00 D), approximately 70–80% will achieve 20/20 uncorrected visual acuity [10–18].

1.2.1.2 Infectious Keratitis

Determining the risk of infection on photoablative procedures is a difficult task due to misdiagnoses and lack of laboratorial information. We may expect an incidence between 0.1:10.000 and 1:10.000, favoring LASIK over PRK [19–21]. Infection has been reported after LASIK with femtosecond laser [22].

Risk factors for the development of infectious keratitis include blepharitis, dry eye, intraoperative epithelial defects, intraoperative contamination, delayed postoperative reepithelialization of the cornea, use of topical corticosteroids, and patients in the health profession [23–25].

Infectious keratitis after LASIK has been divided into infections occurring within the first 2 weeks (early onset) and after 2 weeks to 3 months (late onset) [26]. The organisms responsible for early onset infections include staphylococcal and streptococcal species, whereas organisms more commonly seen in late onset infections include atypical mycobacteria and fungi [27].

In the initial phase of treatment, LASIK flaps should be lifted, cultures taken, the flap bed irrigated with fortified antibiotics, and broad-spectrum topical antibiotics started. For infections with a delayed onset, the use of amikacin may be beneficial in treating atypical mycobacteria [26]. In nonresponsive LASIK infections, flap amputation may be necessary to facilitate antibiotic penetration.

Most infections resolve with mild to moderate loss of best visual acuity [28], but rarely therapeutic penetrating keratoplasty is necessary.

1.3 LASIK

1.3.1 Interface Complications

- *Diffuse lamellar keratitis*

Diffuse lamellar keratitis (DLK) is a white blood cell infiltrate that coalesces between the flap and stromal bed that appears within a few days (1–5) after LASIK [29–31]. Confocal microscopy has confirmed the presence of inflammatory cells in the corneal stroma and interface in DLK [32]. This nonspecific interface inflammation is certainly associated with intraoperative epithelial defects [33] and has been linked to multiple rare potential inciting factors [34].

DLK has been associated with factors such as bacterial endotoxin [35], chemicals or debris [36], surgical gloves [37], and surgical marking pens [38, 39]. Patient factors shown to affect the risk for DLK include Meibomian gland secretions and peripheral immune infiltrates [40, 41] and atopy. Ultimately, DLK is likely the result of how a patient's endogenous factors respond to exogenous exposures [42].

DLK after LASIK has been reported to occur at higher frequency with femtosecond laser flap creation than with microkeratome flap creation. The incidence of DLK is estimated to range from 0.2 to 19.4% after femtosecond laser flap creation [43–47] and from 0.1 to 7.7% after microkeratome flap creation [31, 46, 48–52]. Higher energy level for flap creation with femtosecond laser and larger flap diameter were associated with an increased risk for DLK [53].

DLK is typically classified clinically into four stages as described by Linebarger and colleagues [42]. Stage 1 has inflammatory cells in the far periphery only, which are first present in the corneal stroma and then coalesce in the LASIK interface. Stage 2 has a diffuse infiltrate frequently involving the paracentral and peripheral flap margins but sparing the central axis. Stage 3 has a denser infiltrate within the flap interface, which involves the visual axis and is frequently associated with decreased visual acuity. Stage 4 has a focal, coalesced dense haze with scarring, signifying flap necrosis and usually results in permanent corneal scarring.

- *Pressure-induced stromal keratopathy* (*PISK*)

In the setting of LASIK, PISK is a relatively rapid steroid response resulting in high intraocular pressure with fluid accumulation in the interface. The amount of fluid present may be relatively small, resulting in diffuse haziness in the interface and overlying stroma without an obvious fluid layer [54], or it may be pronounced, resulting in a visible fluid cleft separating the anterior flap from the posterior residual bed [55].

The degree of interface fluid accumulation masks true IOP in various ways when measured using standard approaches. In all cases, actual IOP is greater than IOP measured centrally, and peripheral measurements generate a more accurate IOP.

- *Central toxic keratopathy* (*CTK*)

CTK is a rare, acute, noninflammatory central corneal opacification that can occur within days after uneventful LASIK or PRK [56–62]. Etiology is unknown but may be related to enzymatic degradation of keratocytes [57, 60].

CTK is almost always painless, as opposed to DLK, which in almost all cases has at least a moderate foreign body sensation, and CTK is acute in onset, as opposed to the progression over time to stage 4 DLK. CTK is self-limited and treatment is not warranted [57], while some have advocated aggressive topical steroid use [61] or flap lift and irrigation [63].

- *Epithelial ingrowth*

Epithelial ingrowth at the far periphery is a normal healing response to LASIK flap creation [9], but clinically relevant epithelial ingrowth occurs when a fistula develops under the flap allowing epithelial cell growth into the interface [64]. Most cases can be observed without requiring intervention [64].

For primary LASIK, increased epithelial ingrowth incidence is associated with hyperopic LASIK treatment [65], LASIK after RK [66], epithelial defects during surgery [67], and older age [68]. For LASIK retreatment, increased epithelial ingrowth incidence is associated with the use of contact lenses after retreatment [68] and flap-lift retreatment performed three or more years after primary LASIK [69].

With femtosecond laser flap creation, the overall incidence of visually significant epithelial ingrowth has decreased [70]. The lower incidence of epithelial ingrowth after femtosecond LASIK surgery compared with mechanical microkeratome-assisted LASIK may be attributed to the anatomy of the femtosecond laser-created side cut, in contrast to that created with a mechanical microkeratome, and the creation of less peripheral trauma at the time of flap creation [71].

Treatment depends on the clinical situation. The majority of cases of mild, clinically insignificant ingrowth are managed with observation. Initial surgical treatment for epithelial ingrowth is performed with flap lift, removal of epithelial cells from the posterior surface of the flap and the stromal bed with a blade or similar instrument, and replacement of the flap without sutures or tissue glue [64, 72]. With recurrent episodes of epithelial ingrowth, additional measures are typically taken, including flap sutures [73] or YAG laser treatment [74].

1.3.2 Flap Complications

Irregular flaps related to the microkeratome cut maybe presented as incomplete flaps, free caps, buttonholed flaps, thin flaps, thick flaps, and partially cut flaps [75].

- *Bowman strip and button hole in LASIK flaps*
  The incidence of intraoperative complications related to flap creation during LASIK is between 0.19 [76] and 21.2% [77]. Several explanations have been proposed to account for Bowman strip or "buttonhole" complications, such as steep corneas, partially opened eyes, and microkeratome deficits, such as blade defect and insufficient synchronization between the movement of the blade and microkeratome translational movement. High astigmatism or conjunctival entrapment may also lead to Bowman strip or buttonhole flap [78, 79].
  Some refractive surgeons recommend waiting 3 months, relifting the flap, and bathing the bed with mitomycin C (MMC) followed by surface ablation [75, 80].

- *Early flap displacement after LASIK*

The application of femtosecond laser technology to LASIK flap creation has increased greatly since its

introduction. These lasers have improved the safety and predictability of the lamellar incision step. The majority of the femtosecond laser-assisted flap complications can be well managed without significant effects on refractive outcomes [81].

The incidence of flap displacement during 12-month follow-up period after LASIK has been reported to be extremely low (0.012%). Femtosecond laser has lower incidence of flap displacement than microkeratome [82].

1.3.2.1 Keratectasia

One of the most troublesome complications after LASIK is progressive iatrogenic keratectasia, which can occur up to several months after surgery [83]. Although the actual incidence of ectasia is unknown, it has been estimated to be 0.04–0.6% [84–86]. Several risk factors have been suggested in an attempt to avoid ectasia [87, 88]. However, controversy exists as to the predictability of these factors, and some cases continue to occur without a clear etiological explanation [84, 89]. Ideally, patients at risk of ectasia would be identified prior to laser surgery and be classified as unsuitable candidates for LASIK; however, at present, there is no absolute test, system, or marker that can identify patients at risk of developing ectasia.

Randleman et al. designed the Ectasia Risk Score System, which is a method of preoperative screening based upon the use of risk scales and identification of a number of preoperative parameters that may be associated with increased risk of ectasia [90]. The most common risk factors, in order of significance, include abnormal preoperative corneal topography, low residual stromal bed thickness, young age, thin preoperative corneal thickness, and higher attempted refractive correction. These factors are then amalgamated into a risk scale. However, this risk factor scale may miss a significant proportion of patients at risk of ectasia because other factors also play a role in the risk of ectasia [91–93].

Post-LASIK ectasia can potentially be avoided by careful patient screening preoperatively to identify risk factors which might lead to this complication.

Management of iatrogenic keratectasia consists of penetrating keratoplasty and, more recently, lamellar keratoplasty [94] and collagen cross-linking (CXL) [95]. In fact, with the success observed for CXL in the treatment of progressive keratoconus, some studies have reported on the use of CXL for postoperative keratectasia in very thin corneas [96].

1.3.2.2 High-Order Aberrations After LASIK

LASIK like other corneal refractive surgeries (such as radial keratotomy, photorefractive keratectomy), is designed to modify the central corneal curvature, making it flatter to correct myopia and steeper to correct hyperopia [97]. This surgical modification might influence the optical quality of the cornea, creating aberrations that will lead to distorted images [98].

LASIK eliminates conventional refractive errors (lower-order aberration like myopia, hyperopia, and astigmatism) leaving higher-order aberrations uncorrected or inducing some higher-order aberrations (HOAs) particularly spherical aberrations [99–102] which are thought to be responsible for the patients' complaints of poor quality of vision, even with visual acuity of 20/25 or 20/20, postoperatively.

Wavefront-guided ablations for intraLase treatment have been shown to be effective and predictable in reducing the astigmatism and higher-order aberrations [103–107].

1.3.2.3 Post-LASIK Tear Dysfunction and Dysesthesia

Symptoms of tear dysfunction after LASIK occur in nearly all patients and resolve in the vast majority. Although dry eye complaints are a leading cause of patient discomfort and dissatisfaction after LASIK, the symptoms are not uniform, and the disease is not a single entity. Post-LASIK tear dysfunction syndrome or dry eye is a term used to describe a spectrum of disease encompassing transient or persistent postoperative neurotrophic disease, tear instability, true aqueous tear deficiency, and neuropathic pain states. Neural changes in the cornea and neuropathic causes of ocular surface discomfort may play a separate or synergistic role in the development of symptoms in some patients. Most cases of early postoperative dry eye symptoms resolve with appropriate management, which includes optimizing ocular surface health before and after surgery. Severe symptoms or symptoms persisting after 9 months rarely respond satisfactorily to traditional treatment modalities and require aggressive management [108].

1.3.2.4 Ocular Surface Syndrome

This complex multifactorial entity distresses patients and physicians and is characterized by the following symptoms: dry eye, micropunctate keratitis, decreased and unstable tear film, and decreased best spectacle-corrected visual acuity (BSCVA) and visual quality. Ocular surface syndrome has a neurotrophic etiology, is long lasting, and is difficult to treat [109].

1.3.2.5 Retinal Complications

There are several reports in the literature about retinal complications after LASIK for the correction of myopia. These include macular holes [110–113], retinal tears and detachments [114], retinal hemorrhages [115], and choroidal neovascular membranes [116].

1.4 PRK

1.4.1 Haze

Corneal haze reduces corneal transparency at variable degrees [117, 118]. Subepithelial haze occurs in all patients

1 month after PRK, reaching the greatest intensity at 3–6 months, and then gradually decreasing [119].

Besides the ablation depth, the severity of corneal haze is correlated with excessive ocular UV-B radiation, duration of the epithelial defect, postoperative steroid treatment, and male sex, and with certain population with brown iris [120–122].

Recently, the densitometry program of Pentacam Scheimpflug imaging system (Oculus Optikgeräte GmbH) has been proven to be a useful method for measuring corneal haze [123].

1.4.2 Mitomycin C

The use of intraoperative mitomycin C has raised the expectation for treating higher ametropias with PRK [118, 124–128].

Mitomycin C is an alkylating agent with cytotoxic and antiproliferative effects that reduces the myofibroblast repopulation after laser surface ablation and, therefore, reducing the risk of postoperative corneal haze. It is used prophylactically to avoid haze after primary surface ablation and therapeutically to treat preexisting haze. There is no definite evidence that establishes an exact diopter limit or ablation depth at which to apply prophylactic mitomycin C. It is usually applied at a concentration of 0.2 mg/ml (0.02%) for 12–120 s over the ablated stroma, although some studies suggest that lower concentrations (0.01, 0.002%) could also be effective in preventing haze when treating low to moderate myopia. This dose of mitomycin C has not been associated with any clinically relevant epithelial corneal toxicity. Its effect on the endothelium is more controversial [129].

1.4.3 Keratectasia

Although there are reports of keratectasia that occurred in normal eyes after PRK [130], most of the few cases reported so far are of forme fruste keratoconus that progressed after PRK [131–133] or phototherapeutic keratectomy (PTK) [134, 135].

1.5 Phakic Intraocular Lenses

The option of phakic IOLs (PIOLs) has gained popularity, having usually the widest range of correction (myopia up to 23D, hyperopia up to 21D, and astigmatism up to 7.00D) and being affordable and easily implantable [136–138]. It has potential advantages, including fast visual recovery, preservation of accommodation, and reversibility [139–141]. Compared to LASIK, PIOLs offer a higher range of refractive error correction and better quality of vision for high ametropes [142].

There are two available phakic IOLs now: the iris-fixated Artisan and the posterior chamber implantable Collamer lens (ICL). The Artiflex myopia phakic IOL was developed based on the Artisan platform, with a flexible, convex-concave, 6 mm silicone optic, PMMA haptics [143, 144]. It can achieve precise centration over the pupil and high rotational stability, but requires some surgical skills for enclavation [142]. It also requires some safety limitations like flat iris, endothelial cell count (ECC) of ≥2100 cell/mm^2, scotopic pupil diameter < 6.0 mm, and AC depths of ≥2.8 mm [145, 146]. The Visian ICL is made from Collamer (biocompatible material). Another type of phakic IOLs was angle supported, but is not in use now.

The toric Artisan corrects astigmatism from 1D to 7D, and toric ICL is capable of correcting astigmatism up to 6D. It is a good option especially for high errors with low baseline corneal thickness, shallow AC, and wide scotopic pupils [147, 148].

1.5.1 Common Complications Associated with Phakic IOLs

1.5.1.1 Pupil Ovalization

Eyes with anterior chamber angle-supported phakic IOLs have a tendency to present sectorial iris atrophy and consequent pupil ovalization [149].

1.5.1.2 Endothelial Cell Loss

The long-term impact of anterior chamber PIOL implantation on corneal endothelial cell loss has been a matter of significant research and debate. As a result of numerous randomized clinical trials, the safety of Artisan and Artiflex IOLs is now well established, with reported endothelial cell losses of 4.8% at 6 months, 8.3% at 5 years, and 12.6% at 7 years and long-term maintenance of the hexagonality and the cell coefficient of variation [150–152]. The minimum E-IOL distance from the center of the IOL to minimize the risk of endothelial cell loss was 1.7 mm [153].

Although posterior chamber IOLs have a lower risk of endothelial cell loss, a decrease in 5–10% after 2 years of the surgery may be expected [154].

1.5.1.3 Infection

Risk of infection in intraocular surgeries should follow the incidence of infection in cataract surgery that is approximately 1:1,000 [155–157].

1.5.1.4 Glaucoma

Pupillary block glaucoma has been reported in anterior chamber iris-supported [158], in angle-supported [159, 160],

and in posterior chamber phakic IOLs [161–163]. Preoperative iridectomy is mandatory, but pupillary block has been reported even in the presence of effective iridectomy [163].

1.5.1.5 Cataract

There are two basic cataract types: anterior subcapsular opacification (in cases of ICL) and nuclear cataract (in cases of Artisan). The mean time to nuclear cataract appearance after Artisan IOL implantation was 54.83 ± 22.12, and ICL implantation was 20 ± 1 month [164].

Cataract is the main cause of PIOL explantation, especially in posterior chamber PIOLs [165].

1.5.1.6 Uveitis

Postoperative sterile uveitis has been reported in previous studies [166]. The pathogenesis of uveitis after PIOL implantation is still obscure but may be related to an inflammatory reaction caused by perioperative and postoperative mechanical irritation of the iris. It is possible to detect chronic subclinical inflammation with a laser flare-cell matter after PIOL implantation [166].

Age-related changes in the anatomy of the anterior segment may create a long-term hazard for the implanted eye [167].

1.5.1.7 IOL Dislocation

Traumatic and spontaneous IOL dislocations have been described in anterior chamber iris-supported phakic IOLs [168, 169].

1.5.1.8 Retinal Complications

Implantation of ICL or Artisan phakic IOL demonstrated comparable rates of retinal complications. Anterior chamber PIOL does not increase the risk of retinal detachment or CNVM in patients with myopia [170].

Take-Home Pearls

- Refractive surgery provides a variety of elective procedures to be performed in otherwise healthy eyes. Selecting the best surgical treatment is dependent on knowing all the associated complications.

References

1. Kohnen T, Shajari M. Phakic intraocular lenses. Ophthalmologe. 2016;113(6):529–38.
2. Terzi E, Kern T, Kohnen T. Complications after refractive surgery abroad [article in German]. Ophthalmologe. 2008;105:474–9.
3. Lockington D, Johnson R, Patel DV, McGhee CN. Healthcare and a holiday: the risks of LASIK tourism. Clin Exp Optom. 2014;97:370–2.
4. Lundström M, Manning S, et al. The European registry of quality outcomes for cataract and refractive surgery (EUREQUO): a database study of trends in volumes, surgical techniques and outcomes of refractive surgery. Eye Vis (Lond). 2015;2:8.
5. Broderick KM, Rose K, et al. Wavefront-optimized surface retreatments of refractive error following previous laser refractive surgery: a retrospective study. Eye Vis (Lond). 2016;3:3.
6. AAO Refractive Management/Intervention PPP Panel, Hoskins Center for Quality Eye Care. Refractive Errors & Refractive Surgery PPP – 2013. 2013. http://one.aao. org/preferred-practice-pattern/refractive-errors—surgery-ppp-2013.
7. AAO Quality of Care Secretariat, Hoskins Center for Quality Eye Care. Summary Recommendations for Keratorefractive Laser Surgery – 2013. 2013. http://one. aao.org/clinical-statement/summary-recommendations-lasik—january-2008.
8. El Bahrawy M, Alió JL. Excimer laser 6th generation: state of the art and refractive surgical outcomes. Eye Vis (Lond). 2015;2:6.
9. Dawson DG, Kramer TR, Grossniklaus HE, Waring GO 3rd, Edelhauser HF. Histologic, ultrastructural, and immunofluorescent evaluation of human laser-assisted in situ keratomileusis corneal wounds. Arch Ophthalmol. 2005;123:741–56.
10. Hjortdal JO, Moller-Pedersen T, Ivarsen A, Ehlers N. Corneal power, thickness, and stiffness: results of a prospective randomized controlled trial of PRK and LASIK for myopia. J Cataract Refract Surg. 2005;31(1):21–9.
11. Shortt AJ, Allan BD. Photorefractive keratectomy (PRK) versus laser-assisted in-situ keratomileusis (LASIK) for myopia. Cochrane Database Syst Rev. 2006;2:CD005135.
12. Shortt AJ, Bunce C, Allan BD. Evidence for superior efficacy and safety of LASIK over photorefractive keratectomy for correction of myopia. Ophthalmology. 2006;113(11):1897–908.
13. Wang Z, Chen J, Yang B. Comparison of laser in situ keratomileusis and photorefractive keratectomy to correct myopia from −1.25 to −6.00 diopters. J Refract Surg. 1997;13(6):528–34.
14. Hersh PS, Brint SF, Maloney RK, Durrie DS, Gordon M, Michelson MA, et al. Photorefractive keratectomy versus laser in situ keratomileusis for moderate to high myopia. A randomized prospective study. Ophthalmology. 1998;105(8):1512–22. discussion 1522-3
15. Forseto AS, Nosé RA, Nosé W. PRK versus LASIK for correction of low and moderate myopia [in Portuguese]. Arq Bras Oftalmol. 2000;63:257–62.
16. El-Maghraby A, Salah T, Waring GO 3rd, Klyce S, Ibrahim O. Randomized bilateral comparison of excimer laser in situ keratomileusis and photorefractive keratectomy for 2.50 to 8.00 diopters of myopia. Ophthalmology. 1999;106(3):447–57.
17. El Danasoury MA, El Maghraby A, Klyce SD, Mehrez K. Comparison of photorefractive keratectomy with excimer laser in situ keratomileusis in correcting low myopia (from −2.00 to −5.50 diopters). A randomized study. Ophthalmology. 1999;106(2):411–20. discussion 420-1
18. Lasik Eye Surgery. 2006 July 12, 2006 [cited March 22, 2007]; Available from: http://www.fda.gov/cdrh/LASIK/
19. de Oliveira GC, Solari HP, Ciola FB, Lima AL, Campos MS. Corneal infiltrates after excimer laser photorefractive keratectomy and LASIK. J Refract Surg. 2006;22(2):159–65.
20. Wroblewski KJ, Pasternak JF, Bower KS, Schallhorn SC, Hubickey WJ, Harrison CE, et al. Infectious keratitis after photorefractive keratectomy in the United States army and navy. Ophthalmology. 2006;113(4):520–5.
21. Moshirfar M, Welling JD, Feiz V, Holz H, Clinch TE. Infectious and noninfectious keratitis after laser in situ keratomileusis occurrence, management, and visual outcomes. J Cataract Refract Surg. 2007;33(3):474–83.
22. Lifshitz T, Levy J, Mahler O, Levinger S. Peripheral sterile corneal infiltrates after refractive surgery. J Cataract Refract Surg. 2005;31(7):1392–5.

23. Llovet F, de Rojas V, Interlandi E, et al. Infectious keratitis in 204 586 LASIK procedures. Ophthalmology. 2010;117:232–8. e1–e4
24. Chang MA, Jain S, Azar DT. Infections following laser in situ keratomileusis: an integration of the published literature. Surv Ophthalmol. 2004;49:269–80.
25. Karp CL, Tuli SS, Yoo SH, et al. Infectious keratitis after LASIK. Ophthalmology. 2003;110:503–10.
26. Donnenfeld ED, Kim T, Holland EJ, et al. ASCRS white paper: management of infectious keratitis following laser in situ keratomileusis. J Cataract Refract Surg. 2005;31:2008–11.
27. Bradley Randleman J, Shah RD, Interface Complications LASIK. Etiology, management, & outcomes. J Refract Surg. 2012;28(8):575–86.
28. Mozayan A, Madu A, Channa P. Laser in-situ keratomileusis infection: review and update of current practices. Curr Opin Ophthalmol. 2011;22:233–7.
29. Stulting RD, Randleman JB, Couser JM, Thompson KP. The epidemiology of diffuse lamellar keratitis. Cornea. 2004;23:680–8.
30. Smith RJ, Maloney RK. Diffuse lamellar keratitis. A new syndrome in lamellar refractive surgery. Ophthalmology. 1998;105:1721–6. doi:10.1016/S0161-6420(98)99044-3.
31. Johnson JD, Harissi-Dagher M, Pineda R, Yoo S, Azar DT. Diffuse lamellar keratitis: incidence, associations, outcomes, and a new classification system. J Cataract Refract Surg. 2001;27:1560–6.
32. Buhren J, Baumeister M, Cichocki M, Kohnen T. Confocal microscopic characteristics of stage 1 to 4 diffuse lamellar keratitis after laser in situ keratomileusis. J Cataract Refract Surg. 2002;28:1390–9.
33. Shah MN, Misra M, Wihelmus KR, Koch DD. Diffuse lamellar keratitis associated with epithelial defects after laser in situ keratomileusis. J Cataract Refract Surg. 2000;26:1312–8.
34. Gritz DC. LASIK interface keratitis: epidemiology, diagnosis and care. Curr Opin Ophthalmol. 2011;22:251–5.
35. Holland SP, Mathias RG, Morck DW, Chiu J, Slade SG. Diffuse lamellar keratitis related to endotoxins released from sterilizer reservoir biofilms. Ophthalmology. 2000;107:1227–33. discussion by EJ Holland, 1233–1234
36. Yuhan KR, Nguyen L, Boxer Wachler BS. Role of instrument cleaning and maintenance in the development of diffuse lamellar keratitis. Ophthalmology. 2002;109:400–3. discussion by SN Rao, RJ Epstein, 403–404
37. Hoffman RS, Fine IH, Packer M, Reynolds TP, Van Bebber C. Surgical glove-associated diffuse lamellar keratitis. Cornea. 2005;24:699–704.
38. Hadden OB, McGhee CNJ, Morris AT, Gray TB, Ring CP, Watson ASJ. Outbreak of diffuse lamellar keratitis caused by marking-pen toxicity. J Cataract Refract Surg. 2008;34:1121–4.
39. Rosman M, Chua W-H, Tseng PSF, Wee T-L, Chan W-K. Diffuse lamellar keratitis after laser in situ keratomileusis associated with surgical marker pens. J Cataract Refract Surg. 2008;34:974–9.
40. Fogla R, Rao SK, Padmanabhan P. Diffuse lamellar keratitis: are meibomian secretions responsible? [letter]. J Cataract Refract Surg. 2001;27:493–5.
41. Ambrosio R Jr, Periman LM, Netto MV, Wilson SE. Bilateral marginal sterile infiltrates and diffuse lamellar keratitis after laser in situ keratomileusis. J Refract Surg. 2003;19:154–8.
42. Linebarger EJ, Hardten DR, Lindstrom RL. Diffuse lamellar keratitis: diagnosis and management. J Cataract Refract Surg. 2000;26:1072–7.
43. Choe CH, Guss C, Musch DC, Niziol LM, Shtein RM. Incidence of diffuse lamellar keratitis after LASIK with 15 KHz, 30 KHz, and 60 KHz femtosecond laser flap creation. J Cataract Refract Surg. 2010;36:1912–8.
44. Haft P, Yoo SH, Kymionis GD, Ide T, O'Brien TP, Culbertson WW. Complications of LASIK flaps made by the IntraLase 15- and 30-kHz femtosecond lasers. J Refract Surg. 2009;25: 979–84.
45. Binder PS. One thousand consecutive IntraLase laser in situ keratomileusis flaps. J Cataract Refract Surg. 2006;32:962–9.
46. Gil-Cazorla R, Teus MA, de Benito-Llopis L, Fuentes I. Incidence of diffuse lamellar keratitis after laser in situ keratomileusis associated with the IntraLase 15 kHz femtosecond laser and Moria M2 microkeratome. J Cataract Refract Surg. 2008;34:28–31.
47. Moshirfar M, Gardiner JP, Schliesser JA, Espandar L, Feiz V, Mifflin MD, Chang JC. Laser in situ keratomileusis flap complications using mechanical microkeratome versus femtosecond laser: retrospective comparison. J Cataract Refract Surg. 2010;36:1925–33.
48. Thammano P, Rana AN, Talamo JH. Diffuse lamellar keratitis after laser in situ keratomileusis with the Moria LSK-one and Carriazo-Barraquer microkeratomes. J Cataract Refract Surg. 2003;29:1962–8.
49. McLeod SD, Tham VM-B, Phan ST, Hwang DG, Rizen M, Abbott RL. Bilateral diffuse lamellar keratitis following bilateral simultaneous versus sequential laser in situ keratomileusis. Br J Ophthalmol. 2003;87:1086–7.
50. Hoffman RS, Fine IH, Packer M. Incidence and outcomes of LASIK with diffuse lamellar keratitis treated with topical and oral corticosteroids. J Cataract Refract Surg. 2003;29:451–6.
51. Lin RT, Maloney RK. Flap complications associated with lamellar refractive surgery. Am J Ophthalmol. 1999;127:129–36.
52. Wilson SE, Ambrosio R Jr. Sporadic diffuse lamellar keratitis (DLK) after LASIK. Cornea. 2002;21:560–3. doi:10.1097/00003226-200208000-00005.
53. de Paula FH, et al. Diffuse lamellar keratitis after laser in situ keratomileusis with femtosecond laser flap creation. J Cataract Refract Surg. 2012;38(6):1014–9.
54. Belin MW, Hannush SB, Yau CW, Schultze RL. Elevated intraocular pressure-induced interlamellar stromal keratitis. Ophthalmology. 2002;109:1929–33.
55. Hamilton DR, Manche EE, Rich LF, Maloney RK. Steroid-induced glaucoma after laser in situ keratomileusis associated with interface fluid. Ophthalmology. 2002;109:659–65.
56. Moshirfar M, Hazin R, Khalifa YM. Central toxic keratopathy. Curr Opin Ophthalmol. 2010;21:274–9.
57. Sonmez B, Maloney RK. Central toxic keratopathy: description of a syndrome in laser refractive surgery. Am J Ophthalmol. 2007;143:420–7.
58. Hazin R, Daoud YJ, Khalifa YM. What is central toxic Keratopathy syndrome if it is not diffuse lamellar keratitis grade IV? Middle East Afr J Ophthalmol. 2010;17:60–2.
59. Fraenkel GE, Cohen PR, Sutton GL, Lawless MA, Rogers CM. Central focal interface opacity after laser in situ keratomileusis. J Refract Surg. 1998;14:571–6.
60. Hainline BC, Price MO, Choi DM, Price FW Jr. Central flap necrosis after LASIK with microkeratome and femtosecond laser created flaps. J Refract Surg. 2007;23:233–42.
61. Lyle WA, Jin GJ. Central lamellar keratitis. J Cataract Refract Surg. 2001;27:487–90.
62. Parolini B, Marcon G, Panozzo GA. Central necrotic lamellar inflammation after laser in situ keratomileusis. J Refract Surg. 2001;17:110–2.
63. Tu KL, Aslanides IM. Surgical intervention in central toxic keratopathy. Eur J Ophthalmol. 2012;3:0.
64. Wang MY, Maloney RK. Epithelial ingrowth after laser in situ keratomileusis. Am J Ophthalmol. 2000;129:746–51.
65. Mohamed TA, Hoffman RS, Fine IH, Packer M. Post-laser assisted in situ keratomileusis epithelial ingrowth and its relation to pretreatment refractive error. Cornea. 2011;30:550–2.
66. Randleman JB, Banning CS, Stulting RD. Persistent epithelial ingrowth. Ophthalmology. 2006;113:1468 e1–3.
67. Jabbur NS, Chicani CF, Kuo IC, O'Brien TP. Risk factors in interface epithelialization after laser in situ keratomileusis. J Refract Surg. 2004;20:343–8.

68. Chan CC, Boxer Wachler BS. Comparison of the effects of LASIK retreatment techniques on epithelial ingrowth rates. Ophthalmology. 2007;114:640–2.
69. Caster AI, Friess DW, Schwendeman FJ. Incidence of epithelial ingrowth in primary and retreatment laser in situ keratomileusis. J Cataract Refract Surg. 2010;36:97–101.
70. Kamburoglu G, Ertan A. Epithelial ingrowth after femtosecond laser-assisted in situ keratomileusis. Cornea. 2008;27:1122–5.
71. Kamburoğlu G, Ertan A. Epithelial ingrowth after femtosecond laser-assisted in situ keratomileusis. Cornea. 2008;27(10):1122–5. doi:10.1097/ICO.0b013e3181731439.
72. Rapuano CJ. Management of epithelial ingrowth after laser in situ keratomileusis on a tertiary care cornea service. Cornea. 2010;29:307–13.
73. Güell JL, Verdaguer P, et al. Epithelial ingrowth after LASIK: visual and refractive results after cleaning the interface and suturing the lenticule. Cornea. 2014;33(10):1046–50.
74. Ayala MJ, Alio JL, Mulet ME, De La Hoz F. Treatment of laser in situ keratomileusis interface epithelial ingrowth with neodymium:yytrium-aluminum-garnet laser. Am J Ophthalmol. 2008;145:630–4.
75. Leung AT, Rao SK, Cheng AC, Yu EW, Fan DS, Lam DS. Pathogenesis and management of laser in situ keratomileusis flap buttonhole. J Cataract Refract Surg. 2000;26(3):358–62.
76. Al-Mezaine HS, Al-Amro SA, Al-Obeidan S. Incidence, management, and visual outcomes of buttonhole laser in situ keratomileusis flaps. J Cataract Refract Surg. 2009;35:839–45.
77. Al-Mezaine HS, Al-Amro SA, Al-Fadda A, Al-Obeidan S. Outcomes of retreatment after aborted laser in situ keratomileusis due to flap complications. Middle East Afr J Ophthalmol. 2011;18:232–7.
78. Pulaski JP. Etiology of buttonhole flaps [letter]. J Cataract Refract Surg. 2000;26:1270–1.
79. Lane HA, Swale JA, Majmudar PA. Prophylactic use of Mitomycin-C in the management of a buttonhole LASIK flap. J Cataract Refract Surg. 2003;29:390–2.
80. Rubinfeld RS, Hardten DR, Donnenfeld ED, et al. To lift or recut: changing trends in LASIK enhancement. J Cataract Refract Surg. 2003;29:2306–17.
81. Dos Santos AM, Torricelli AA, et al. Femtosecond laser-assisted LASIK flap complications. J Refract Surg. 2016;32(1):52–9.
82. Clare G, Moore TC, et al. Early flap displacement after LASIK. Ophthalmology. 2011;118(9):1760–5.
83. Randleman JB. Post-laser in-situ keratomileusis ectasia: current understanding and future directions. Curr Opin Ophthalmol. 2006;17:406–12.
84. Binder PS. Analysis of ectasia after laser in situ keratomileusis: risk factors. J Cataract Refract Surg. 2007;33:1530–8.
85. Chen MC, Lee N, Bourla N, Hamilton DR. Corneal biomechanical measurements before and after laser in situ keratomileusis. J Cataract Refract Surg. 2008;34:1886–91.
86. Kirwan C, O'Malley D, O'Keefe M. Corneal hysteresis and corneal resistance factor in keratectasia: finding using the Reichert ocular response analyzer. Ophtalmologica. 2008;222:334–7.
87. Randleman JB, Russell B, Ward MA, Thompson KP, Stulting RD. Risk factors and prognosis for corneal ectasia after LASIK. Ophthalmology. 2003;110:267–75.
88. Rabinowitz YS. Ectasia after laser in situ keratomileusis. Curr Opin Ophthalmol. 2006;17:421–6.
89. Klein SR, Epstein RJ, Randleman JB, Stulting RD. Corneal ectasia after laser in situ keratomileusis in patients without apparent preoperative risk factors. Cornea. 2006;25:388–403. doi:10.1097/01.ico.0000222479.68242.77.
90. Randleman JB, Woodward M, Lynn MJ, Stulting RD. Risk assessment for ectasia after corneal refractive surgery. Ophthalmology. 2008;115:37–50.
91. Chan CC, Hodge C, Sutton G. External analysis of the Randleman Ectasia risk factor score system: a review of 36 cases of post LASIK ectasia. Clin Experiment Ophthalmol. 2010;38:335–40.
92. Ambrósio R Jr, Dawson DG, Salomão M, Guerra FP, Caiado AL, Belin MW. Corneal ectasia after LASIK despite low preoperative risk: tomographic and biomechanical findings in the unoperated, stable, fellow eye. J Refract Surg. 2010;26:906–11.
93. Binder PS, Trattler WB. Evaluation of a risk factor scoring system for corneal ectasia after LASIK in eyes with normal topography. J Refract Surg. 2010;26:241–50.
94. Kucumen RB, Yenerel NM, Gorgun E, Oncel M. Penetrating keratoplasty for corneal ectasia after laser in situ keratomileusis. Eur J Ophthalmol. 2008;18:695–702.
95. Spadea L. Collagen crosslinking for ectasia following PRK performed in excimer laser-assisted keratoplasty for keratoconus. Eur J Ophthalmol. 2012;22:274–7.
96. Spadea L, Mencucci R. Transepithelial corneal collagen crosslinking in ultrathin keratoconic corneas. Clin Ophthalmol. 2012;6:1785–92.
97. Chalita MR, Chavala S, Xu M, Krueger RR. Wavefront analysis in post-LASIK eyes and its correlation with visual symptoms, refraction, and topography. Ophthalmology. 2004;111(3):447–53.
98. Oshika T, Miyata K, Tokunaga T, Samejima T, Amano S, Tanaka S, Hirohara Y, Mihashi T, Maeda N, Fujikado T. Higher order wavefront aberrations of cornea and magnitude of refractive correction in laser in situ keratomileusis. Ophthalmology. 2002;109(6):1154–8.
99. Tran DB, Sarayba MA, Bor Z, Garufis C, Duh Y-J, Soltes CR, Juhasz T, Kurtz RM. Randomized prospective clinical study comparing induced aberrations with IntraLase and Hansatome flap creation in fellow eyes: potential impact on wavefront-guided laser in situ keratomileusis. J Cataract Refract Surg. 2005;31(1):97–105.
100. Moreno-Barriuso E, Lloves JM, Marcos S, Navarro R, Llorente L, Barbero S. Ocular aberrations before and after myopic corneal refractive surgery: LASIK induced changes measured with laser ray tracing. Invest Ophthalmol Vis Sci. 2001;42(6):1396–403.
101. Ma L, Atchison DA, Albietz JM, Lenton LM, McLennan SG. Wavefront aberrations following laser in situ keratomileusis and refractive lens exchange for hypermetropia. J Refract Surg. 2003;20(4):307–16.
102. Buzzonetti L, Petrocelli G, Valente P, Tamburrelli C, Mosca L, Laborante A, Balestrazzi E. Comparison of corneal aberration changes after laser in situ keratomileusis performed with mechanical microkeratome and IntraLase femtosecond laser: 1-year follow-up. Cornea. 2008;27(2):174–9.
103. Stonecipher K, Ignacio TS, Stonecipher M. Advances in refractive surgery: microkeratome and femtosecond laser flap creation in relation to safety, efficacy, predictability, and biomechanical stability. Curr Opin Ophthalmol. 2006;17(4):368–72. doi:10.1097/01.icu.0000233957.88509.2d.
104. Farjo AA, Sugar A, Schallhorn SC, Majmudar PA, Tanzer DJ, Trattler WB, Cason JB, Donaldson KE, Kymionis GD. Femtosecond lasers for LASIK flap creation: a report by the American Academy of ophthalmology. Ophthalmology. 2013;120(3):e5–20.
105. Sáles CS, Manche EE. One-year eye-to-eye comparison of wavefront-guided versus wavefront-optimized laser in situ keratomileusis in hyperopes. Clin Ophthalmol. 2014;8:2229.
106. Padmanabhan P, Mrochen M, Basuthkar S, Viswanathan D, Joseph R. Wavefront-guided versus wavefront-optimized laser in situ keratomileusis: contralateral comparative study. J Cataract Refract Surg. 2008;34(3):389–97.
107. Tran DB, Shah V. Higher order aberrations comparison in fellow eyes following intraLase LASIK with wavelight allegretto and custom cornea LADArvision4000 systems. J Refract Surg. 2006;22:S961.

108. Nettune GR, et al. Post-LASIK tear dysfunction and dysesthesia. Ocul Surf. 2010;8(3):135–45.
109. Alio JL, Pastor S, et al. Treatment of ocular surface syndrome after LASIK with autologous platelet-rich plasma. J Refract Surg. 2007;23(6):617–9.
110. Arevalo JF, Rodriguez FJ, Rosales-Meneses JL, Dessouki A, Chan CK, Mittra RA, Ruiz-Moreno JM. Vitreoretinal surgery for macular hole after laser assisted in situ keratomileusis for the correction of myopia. Br J Ophthalmol. 2005;89:1423–6.
111. Arevalo JF, Mendoza AJ, Velez-Vazquez W, Rodriguez FJ, Rodriguez A, Rosales-Meneses JL, et al. Full-thickness macular hole after LASIK for the correction of myopia. Ophthalmology. 2005;112:1207–12.
112. Ruiz-Moreno JM, Artola A, Pérez-Santonja JJ, Alió JL. Macular hole in a myopic eye after laser in situ keratomileusis. J Refract Surg. 2002;18:746–9.
113. Chan CK, Lawrence FC. Macular hole after laser in situ keratomileusis and photorefractive keratectomy. Am J Ophthalmol. 2001;131:666–7. doi:10.1016/S0002-9394(00)00855-2.
114. Al-Rashaed S, Al-Halafi AM. Retinal detachment after laser in situ keratomileusis. Middle East Afr J Ophthalmol. 2011;18:224–7.
115. Principe AH, Lin DY, Small KW, Aldave AJ. Macular hemorrhage after laser in situ keratomileusis (LASIK) with femtosecond laser flap creation. Am J Ophthalmol. 2004;138:657–9.
116. Ruiz-Moreno JM, Pérez-Santonja JJ, Alió JL. Choroidal neovascularization in myopic eyes after laser-assisted in situ keratomileusis. Retina. 2001;21:115–20.
117. Razmjoo H, Kooshanmehr MR, Peyman A, Kor Z, Mohammadesmaeil E. Comparison of standard and low dose intraoperative mitomycin C in prevention of corneal haze after photorefractive keratectomy. Int J Prev Med. 2013;4:204–7.
118. Netto MV, Mohan RR, Sinha S, Sharma A, Gupta PC, Wil-son SE. Effect of prophylactic and therapeutic mitomycinC on corneal apoptosis, cellular proliferation, haze, and long-term keratocyte density in rabbits. J Refract Surg. 2006;22:562–74.
119. Alio JL, Javaloy J. Corneal inflammation following corneal photoablative refractive surgery with excimer laser. Surv Ophthalmol. 2013;58:11–25.
120. Kremer I, Ehrenberg M, Levinger S. Delayed epithelial healing following photorefractive keratectomy with mitomycin C treatment. Acta Ophthalmol. 2012;90:271–6.
121. de Medeiros FW, Mohan RR, Suto C, Sinhá S, Bonilha VL, Chaurasia SS, et al. Haze development after photorefractive keratectomy: mechanical vs ethanol epithelial removalin rabbits. J Refract Surg. 2008;24:923–7.
122. Resch MD, Nagy ZZ, Szentmáry N, Máthé M, Kovalszky I, Süveges I. Spatial distribution of keratin sulfate in the rabbit cornea following photorefractive keratectomy. J Refract Surg. 2005;21:485–93.
123. Takacs AI, Mihaltz K, Nagy ZZ. Corneal density with the Pentacam after photorefractive keratectomy. J Refract Surg. 2011;27:269–77.
124. Bedei A, Marabotti A, Giannecchini I, Ferretti C, Montagnani M, Martinucci C, et al. Photorefractive keratectomy in high myopic defects with or without intraoperative mitomycin C: 1-year results. Eur J Ophthalmol. 2006;16(2):229–34.
125. Netto MV, Chalita MR, Krueger RR. Corneal haze following PRK with mitomycin C as a retreatment versus prophylactic use in the contralateral eye. J Refract Surg. 2007;23(1):96–8.
126. Carones F, Vigo L, Scandola E. Wavefront-guided treatment of symptomatic eyes using the LADAR6000 excimer laser. J Refract Surg. 2006;22(9):S983–9.
127. Chalita MR, Roth AS, Krueger RR. Wavefront-guided surface ablation with prophylactic use of mitomycin C after a buttonhole laser in situ keratomileusis flap. J Refract Surg. 2004;20(2):176–81.
128. Carones F, Vigo L, Scandola E, Vacchini L. Evaluation of the prophylactic use of mitomycin-C to inhibit haze formation after photorefractive keratectomy. J Cataract Refract Surg. 2002;28(12):2088–95. doi:10.1016/S0886-3350(02)01701-7.
129. Teus MA, de Benito-Llopis L, Alió JL. Mitomycin C in corneal refractive surgery. Surv Ophthalmol. 2009;54(4):487–502.
130. Malecaze F, Coullet J, Calvas P, Fournie P, Arne JL, Brodaty C. Corneal ectasia after photorefractive keratectomy for low myopia. Ophthalmology. 2006;113(5):742–6. doi:10.1016/j.ophtha.2005.11.023.
131. Lovisolo CF, Fleming JF. Intracorneal ring segments for iatrogenic keratectasia after laser in situ keratomileusis or photorefractive keratectomy. J Refract Surg. 2002;18(5):535–41.
132. Javadi MA, Mohammadpour M, Rabei HM. Keratectasia after LASIK but not after PRK in one patient. J Refract Surg. 2006;22(8):817–20.
133. Seiler T, Koufala K, Richter G. Iatrogenic keratectasia after laser in situ keratomileusis. J Refract Surg. 1998;14(3):312–7.
134. Miyata K, Takahashi T, Tomidokoro A, Ono K, Oshika T. Iatrogenic keratectasia after phototherapeutic keratectomy. Br J Ophthalmol. 2001;85(2):247–8.
135. Dean SJ, McGhee CN. Keratectasia after PTK. Br J Ophthalmol. 2002;86(4):486.
136. Stulting RD, John ME, Maloney RK, et al. Three-year results of Artisan/Verisyse phakic intraocular lens implantation. Results of the United States food and drug administration clinical trial. Ophthalmology. 2008;115:464–72. e461
137. Alió JL, Pérez-Santonja JJ. Refractive surgery with Phakic IOLs: fundamentals and clinical practice. New Delhi: Jaypee Brothers; 2013.
138. Alio JL, Pena-Garcia P, Abdulla GF, et al. Comparison of iris-claw and posterior chamber collagen copolymer phakic intraocular lenses in keratoconus. J Cataract Refract Surg. 2014;40:383–94.
139. Al-Dreihi MG, Louka BI, Anbari AA. Artisan iris-fixated toric phakic intraocular lens for the correction of high astigmatism after deep anterior lamellar keratoplasty. Digit J Ophthalmol. 2013;19:39–41.
140. Gomez-Bastar A, Jaimes M, Graue-Hernandez EO, et al. Long-term refractive outcomes of posterior chamber phakic (spheric and toric implantable collamer lens) intraocular lens implantation. Int Ophthalmol. 2014;34:583–90.
141. Alfonso JF, Lisa C, Alfonso-Bartolozzi B, et al. Collagen copolymer toric phakic intraocular lens for myopic astigmatism: one-year follow-up. J Cataract Refract Surg. 2014;40:1155–62.
142. Dick HB, Elies D. In: Alió JL, Pérez-Santonja JJ, editors. Phakic Intraocular Lenses for the correction of Astigmatism. In: Refractive surgery with phakic IOLs, fudamentals and clinical practice. 2nd ed. New Delhi: Jaypee Brothers; 2013. p. 141–5.
143. Tehrani M, Dick HB. Short-term follow-up after implantation of a foldable iris-fixated intraocular lens in phakic eyes. Ophthalmology. 2005;112:2189–95.
144. Georgoudis P, Tappin MJ. Artisan phakic IOL for the correction of ametropia after deep anterior lamellar keratoplasty. J Refract Surg. 2010;26:87.
145. Baikoff G. Anterior segment OCT and phakic intraocular lenses: a perspective. J Cataract Refract Surg. 2006;32:1827–35.
146. Doors M, Cals DW, Berendschot TT, et al. Influence of anterior chamber morphometrics on endothelial cell changes after phakic intraocular lens implantation. J Cataract Refract Surg. 2008;34:2110–8.
147. Alfonso JF, Lisa C, Abdelhamid A, et al. Posterior chamber phakic intraocular lenses after penetrating keratoplasty. J Cataract Refract Surg. 2009;35:1166–73.
148. Iovieno A, Guglielmetti S, Capuano V, et al. Correction of post-keratoplasty ametropia in keratoconus patients using a toric implantable Collamer lens. Eur J Ophthalmol. 2013;23:361–7.

149. Akil H, Dhubhghaill SN, Tassignon MJ. Iris atrophy and erosion caused by an anterior-chamber angle-supported phakic intraocular lens. J Cataract Refract Surg. 2015;41(1):226–9.
150. Doors M, Budo CJ, Christiaans BJ, et al. Artiflex toric foldable phakic intraocular lens: short-term results of a prospective European multicenter study. Am J Ophthalmol. 2012;154(4):730–739. e2.
151. Saxena R, Boekhoorn SS, Mulder PG, Noordzij B, van Rij G, Luyten GP. Long-term follow-up of endothelial cell change after Artisan phakic intraocular lens implantation. Ophthalmology. 2008;115(4):608–13.
152. Benedetti S, Casamenti V, Benedetti M. Long-term endothelial changes in phakic eyes after Artisan intraocular lens implantation to correct myopia: five-year study. J Cataract Refract Surg. 2007;33(5):784–90.
153. Ferreira TB, Portelinha J. Endothelial distance after phakic iris-fixated intraocular lens implantation: a new safety reference. Clin Ophthalmol. 2014;8:255–61.
154. Jimenez-Alfaro I, Benitez del Castillo JM, Garcia-Feijoo J, Gil de Bernabe JG, Serrano de La Iglesia JM. Safety of posterior chamber phakic intraocular lenses for the correction of high myopia: anterior segment changes after posterior chamber phakic intraocular lens implantation. Ophthalmology. 2001;108(1):90–9.
155. Kattan HM, Flynn HW Jr, Pflugfelder SC, Robertson C, Forster RK. Nosocomial endophthalmitis survey. Current incidence of infection after intraocular surgery. Ophthalmology. 1991;98(2):227–38.
156. Marty N, Malavaud S. Epidemiology of nosocomial infections after cataract surgery and role of the infection control committee in prevention. Bull Acad Natl Med. 2002;186(3):635–45. discussion 645-8
157. Haapala TT, Nelimarkka L, Saari JM, Ahola V, Saari KM. Endophthalmitis following cataract surgery in southwest Finland from 1987 to 2000. Graefes Arch Clin Exp Ophthalmol. 2005;243(10):1010–7.
158. Budo C, Hessloehl JC, Izak M, Luyten GP, Menezo JL, Sener BA, et al. Multicenter study of the Artisan phakic intraocular lens. J Cataract Refract Surg. 2000;26(8):1163–71.
159. Leccisotti A. Angle-supported phakic intraocular lenses in hyperopia. J Cataract Refract Surg. 2005;31(8):1598–602.
160. Ardjomand N, Kolli H, Vidic B, El-Shabrawi Y, Faulborn J. Pupillary block after phakic anterior chamber intraocular lens implantation. J Cataract Refract Surg. 2002;28(6):1080–1.
161. Smallman DS, Probst L, Rafuse PE. Pupillary block glaucoma secondary to posterior chamber phakic intraocular lens implantation for high myopia. J Cataract Refract Surg. 2004;30(4):905–7.
162. Hoyos JE, Dementiev DD, Cigales M, Hoyos-Chacon J, Hoffer KJ. Phakic refractive lens experience in Spain. J Cataract Refract Surg. 2002;28(11):1939–46.
163. Bylsma SS, Zalta AH, Foley E, Osher RH. Phakic posterior chamber intraocular lens pupillary block. J Cataract Refract Surg. 2002;28(12):2222–8.
164. Menezo JL, Peris-Martinez C, Cisneros AL, Martinez-Costa R. Phakic intraocular lenses to correct high myopia: adatomed, staar, and artisan. J Cataract Refract Surg. 2004;30:33–44. doi:10.1016/j.jcrs.2003.11.023.
165. Alió JL, Toffaha BT, Peña-Garcia P, Sádaba LM, Barraquer RI. Phakic intraocular lens explantation: causes in 240 cases. J Refract Surg. 2015;31(1):30–5.
166. Barsam A, Allan BD. Excimer laser refractive surgery versus phakic intraocular lenses for the correction of moderate to high myopia. Cochrane Database Syst Rev. 2010;5:CD007679.
167. Alio JL, Abbouda A, Peña-Garcia P. Anterior segment optical coherence tomography of long-term phakic angle-supported intraocular lenses. Am J Ophthalmol. 2013;156(5):894–901.e2.
168. Menezo JL, Avino JA, Cisneros A, Rodriguez-Salvador V, Martinez-Costa R. Iris claw phakic intraocular lens for high myopia. J Refract Surg. 1997;13(6):545–55.
169. Perez-Santonja JJ, Alio JL, Jimenez-Alfaro I, Zato MA. Surgical correction of severe myopia with an angle-supported phakic intraocular lens. J Cataract Refract Surg. 2000;26(9):1288–302.
170. Al-Abdullah AA, Al-Falah MA, Al-Rasheed SA, Khandekar R, Suarez E, Arevalo JF. Retinal complications after anterior versus posterior chamber Phakic intraocular lens implantation in a myopic cohort. J Refract Surg. 2015;31(12):814–9.

2 Influence of Refractive Surgery Complications on Quality of Life

Konrad Pesudovs

Core Messages

- A number of questionnaires exist for the measurement of quality of life (QoL) for refractive surgery patients, but validity varies among questionnaires.
- Rasch analysis is important in the development of questionnaires to optimize question inclusion and unidimensionality and to provide valid linear scoring.
- A quality-of-life instrument should include a breadth of content areas, e.g., well-being, convenience, and concerns, not just functioning or satisfaction.
- Quality-of-life instruments readily demonstrate the benefits of refractive surgery.
- A sound QoL instrument is also sensitive to the negative impacts of surgical complications, providing an insight into the real impact of the intervention on the person.

2.1 Introduction

It has been customary to evaluate the success of refractive surgery using objective clinical measures such as postoperative uncorrected visual acuity (UCVA) and residual refractive error [1]. However, these measures do not necessarily correlate well with patients' postoperative subjective impressions [2]. Ultimately, the patient's perspective is an important outcome of refractive surgery, and a number of instruments have been developed to assess quality of life (QoL), including the Quality of Life Impact of Refractive Correction (QIRC) questionnaire, [3] the Refractive Status Vision Profile (RSVP) [4], and the National Eye Institute Refractive Quality of Life (NEI-RQL) [5]. While these instruments, and others, have been used to show the improvement in QoL that occurs with laser refractive surgery, [2, 5–9] a sound QoL instrument should also be sensitive to the effect of complications from refractive surgery.

The purpose of this chapter is to outline the key issues in QoL measurement and discuss the instruments available for use, and to specifically summarize what is known about the impact of the complications of refractive surgery on quality of life.

2.2 Measurement Concepts

Perhaps the most important issue in questionnaire selection is the validity of the scoring system. Without this, the information gathered is meaningless. The RSVP and NEI-RQL instruments use traditional summary scoring methods where an overall score is derived through summative scoring of responses [10]. Summary scoring is based on the hypothesis that all questions have equal importance and response categories are accordingly scaled to have equal value with uniform increments from category to category. For example, in a summary-scaled visual disability questionnaire, the Activities of Daily Vision Scale (ADVS), [11] "a little difficulty" scores 4, while "extreme difficulty" is twice as bad and scores 2, and "unable to perform the activity due to vision" is similarly two times worse with a score of 1. The same scale is applied across all questions. This rationale of "one size fits all" is flawed, and Rasch analysis has been used to confirm that differently weighted response categories are necessary to provide a valid and contextual scale that truly represents QoL [12]. For instance, the ADVS questionnaire ascribes the same value to "a little difficulty" regarding visual ability "driving at night" as "a little difficulty" with "driving during the day" though the former is by far the more difficult and complex task and it defies logic to equate the two.

Rasch analysis is a new approach to questionnaire development that utilizes modern statistical methods to

K. Pesudovs, Ph.D.
Department of Optometry, Flinders University,
Adelaide, SA 5001, Australia
e-mail: Konrad.Pesudovs@flinders.edu.au

J.L. Alio, D.T. Azar (eds.), *Management of Complications in Refractive Surgery*,
https://doi.org/10.1007/978-3-319-60561-6_2

measure health outcomes in a meaningful way. It incorporates an appropriate weighting factor for each QoL measure to provide true linear scoring and improved validity in terms of question inclusion and demonstration of unidimensionality [13–15].

2.3 Instruments

2.3.1 The Quality-of-Life Impact of Refractive Correction (QIRC) Questionnaire

Pesudovs et al. developed and validated the Quality of Life Impact of Refractive Correction (QIRC) questionnaire [3] to measure the comprehensive impact of refractive correction on QoL. Visual function, symptoms, convenience, cost, health concerns, and well-being are included in the content of this instrument which was rigorously developed using literature review, expert opinion, and focus groups. Content was determined using a pilot questionnaire with Rasch analysis for item reduction; [16] this resulted in the final 20-item questionnaire (Table 2.1, available in full at konrad.pesudovs.com/konrad/questionnaire.html). QIRC is ratified as a valid and reliable measure of refractive correction-related QoL by both Rasch analysis and standard psychometric techniques [3, 13]. QIRC scores are reported on a 0–100 scale which is free of floor and ceiling effects with a higher score representing better QoL and the average score being close to 50 units. QIRC has been used for measuring outcomes of refractive surgery [7, 17–19] and for comparing the QoL of patients wearing spectacles, contact lenses, or post-refractive surgery [20].

The QIRC questionnaire effectively differentiates between spectacle wearers, contact lens wearers, and post-refractive surgery patients—with the refractive surgery group having a better QIRC score (50.23 ± 6.31) than contact lens wearers (46.70 ± 5.49, $p < 0.01$) and spectacle wearers (44.13 ± 5.86, $p < 0.001$) [21]. There were significant differences between scores on 16 of the 20 questions; of the remaining four questions, two health concerns and two well-being questions did not detect differences between groups. QIRC scores have also been shown to improve after LASIK refractive surgery from a mean ± SD of 40.07 ± 4.30 to 53.09 ± 5.25 [7]. Similar improvements have also been demonstrated with phakic lens implantation, femtosecond LASIK, and small-incision lenticule extraction [17–19].

Individual item analysis showed 15 of the 20 items demonstrated statistically significant improvement. Patients reported improved QoL on all five convenience items, both economic items, all four health concern items, and on 4 of the 7 items in the well-being domain (Fig. 2.1).

Table 2.1 The 20 items included in the QIRC questionnaire

	Item description
1	How much difficulty do you have driving in glare conditions?
2	During the past month, how often have you experienced your eyes feeling tired or strained?
3	How much trouble is not being able to use off-the-shelf (nonprescription) sunglasses?
4	How much trouble is having to think about your spectacles or contact lenses or your eyes after refractive surgery before doing things, e.g., traveling, sport, going swimming?
5	How much trouble is not being able to see when you wake up, e.g., to go to the bathroom, look after a baby, see alarm clock?
6	How much trouble is not being able to see when you are on the beach or swimming in the sea or pool, because you do these activities without spectacles or contact lenses?
7	How much trouble are your spectacles or contact lenses when you wear them when using the gym/doing keep-fit classes/circuit training, etc.?
8	How concerned are you about the initial and ongoing cost to buy your current spectacles/contact lenses/refractive surgery?
9	How concerned are you about the cost of unscheduled maintenance of your spectacles/contact lenses/refractive surgery, e.g., breakage, loss, new eye problems?
10	How concerned are you about having to increasingly rely on your spectacles or contact lenses since you started to wear them?
11	How concerned are you about your vision not being as good as it could be?
12	How concerned are you about medical complications from your choice of optical correction (spectacles, contact lenses, and/or refractive surgery)?
13	How concerned are you about eye protection from ultraviolet (UV) radiation?
14	During the past month, how much of the time have you felt that you have looked your best?
15	During the past month, how much of the time have you felt that you think others see you the way you would like them to (e.g., intelligent, sophisticated, successful, cool, etc.)?
16	During the past month, how much of the time have you felt complimented/flattered?
17	During the past month, how much of the time have you felt confident?
18	During the past month, how much of the time have you felt happy?
19	During the past month, how much of the time have you felt able to do the things you want to do?
20	During the past month, how much of the time have you felt eager to try new things?

2.3.2 The Refractive Status Vision Profile (RSVP)

The RSVP was developed almost exclusively on a refractive surgery population (92% of subjects), so it is really only valid for refractive surgery [4]. Its 42 items fall into the domains of concern (6), expectations (2), physical/social functioning (11), driving (3), symptoms (5), glare (3), optical problems (5), and problems with corrective lenses (7)

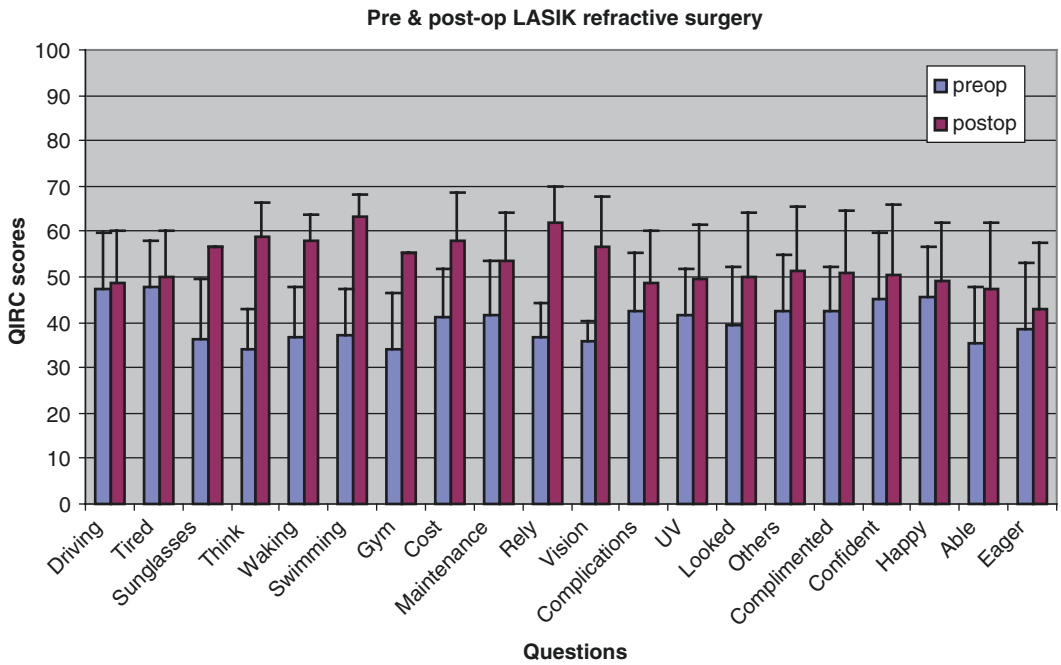

Fig. 2.1 Pre- and post-LASIK mean (error bars ± 1SD) responses on each QIRC question

[9]. The RSVP produces an overall score and subscale scores. The RSVP has been shown to be sensitive to QoL changes related to visual functioning and refractive error and is responsive to refractive surgery [9]. Improvements after laser refractive surgery occurred in the subscales: expectations, physical, and social functioning and problems with corrective lenses. The RSVP has also demonstrated improvements with topographically guided LASIK and phakic lens implantation [22, 47].

The RSVP was developed using traditional techniques, but its psychometric properties were reevaluated by Garamendi et al. and Gothwal et al. using Rasch analysis [23, 24]. The original 42-item questionnaire showed poor targeting of items to patient QoL, items with a ceiling effect, underutilized response categories, and a high level of redundancy [23]. None of the subscales were shown to have adequate measurement properties [24]. The subscales could not be repaired, but Rasch analysis-guided response scale restructuring and item reduction to a 20-item instrument, improved internal consistency and precision for discriminating people. Fourteen items relating to functioning and driving were reduced to 5 items, and 8 related to symptoms and glare were reduced to 3. This is consistent with the content of the QIRC questionnaire, in which Rasch analysis identified that patients with corrected refractive error experienced few problems with visual function, and issues of convenience, cost, health concerns, and well-being were more influential on QoL [3]. Perhaps the reason why the original RSVP was so heavily weighted with functioning and symptoms questions was because the items were principally determined by clinicians [4], who tend to deal with patients' presenting complaints of symptoms or functional difficulties, instead of using more objective methodology to discover the less acute but still important QoL issues.

2.3.3 The National Eye Institute Refractive Quality of Life (NEI-RQL)

The NEI-RQL is a conventionally developed 42-item questionnaire that included subscales related to clarity of vision, expectations, near and far vision, diurnal fluctuations, activity limitations, glare, symptoms, dependence on correction, worry, suboptimal correction, appearance, and satisfaction. The development and validation of the NEI-RQL was spread across 3 papers, and despite rigorous work with focus groups, there is no report on how the final 42 items were selected [5, 25, 26]. However, the NEI-RQL can discriminate between modes of refractive correction and is sensitive to QoL changes related to visual functioning and refractive error [27, 28]. Studies have used the NEI-RQL to demonstrate improved QoL after LASIK [5, 29–31], posterior chamber phakic lens implantation [32, 33], and refractive lens exchange with multifocal intraocular lens implantation [34–36].

The psychometric properties of the NEI-RQL have been examined using Rasch analysis [37, 38]. The NEI-RQL does not produce an overall score, but a score for each of 12 subscales. None of these 12 subscales demonstrated sufficient person separation so as to discriminate people [38]. Therefore,

the NEI-RQL cannot make valid measurement. The NEI-RQL, like the RSVP, also showed problems with the response scales, item misfit, and targeting of items to persons [37, 38]. A specific problem for the NEI-RQL appeared to exist in the way questions were asked with 16 different questions and response formats for 42 questions causing noise, particularly among visual symptoms questions, where frequency and severity were interchanged, yet should have been kept as separate constructs. Attempts to reorganize the NEI-RQL to repair it proved unsuccessful [31, 37].

2.3.4 The Quality of Vision Questionnaire (QoV)

The Quality of Vision Questionnaire (QoV) was not designed to measure quality of life with refractive surgery comprehensively like QIRC, RSVP, and NEI-RQL, instead it measures a single quality-of-life domain: visual symptoms. Since visual symptoms represent an important patient-reported outcome of refractive surgery, the QoV deserves to be covered here. The QoV requires ratings of ten visual symptoms (glare, haloes, starbursts, hazy vision, blurred vision, distortion, double of multiple images, fluctuation in your vision, focusing difficulties, difficulty judging distance, or depth perception) in three constructs (frequency, severity, and bothersomeness) [20]. Therefore, 30 ratings are made. The QoV was developed using focus groups, a pilot questionnaire, Rasch analysis-guided item reduction, and exploration of its psychometric properties. The QoV is rated as having excellent psychometric properties [13]. The three scales, frequency, severity, and bothersomeness, have been shown to measure different constructs and, therefore, are not interchangeable [39]. This is consistent with the commonly observed high rates of glare and halos after refractive surgery (frequency) but very low rates of dissatisfaction (bothersomeness) [40]. The QoV questionnaire provides three scores of visual symptoms on a 100-unit scale.

The QoV has been used to show that both myopic and hyperopic LASEK lead to less visual symptoms postoperatively than preoperatively [41]. The QoV has been used to assess the outcome of bi-aspheric multifocal central presby-LASIK treatment [42]. The QoV questionnaire has also been used in refractive lens exchange with monofocal and multifocal intraocular lenses [43–45]. The focus of the QoV instrument being visual symptoms makes it ideal for detecting visual complications of refractive surgery.

2.3.5 Others

The Myopia Specific Quality of Life and the Canadian Refractive Surgery Research Group Questionnaires have been conventionally validated and shown to be responsive to refractive surgery [46, 47]. Other studies that report QoL issues before and after refractive surgery have used informal, nonvalidated questionnaires, [2, 6, 8, 48, 49] providing only limited evidence.

2.4 Complications and Quality of Life

2.4.1 QIRC

Two studies using the QIRC questionnaire have highlighted QoL problems after LASIK. In a cross-sectional comparison of spectacle, contact lens, and refractive surgery patients, the post-refractive surgery group was also asked to report any visual disturbances that arose after their surgery, and a small number optionally reported post-operative complications. Nine LASIK patients (8.6%) volunteered written comments regarding their postoperative status (including poor vision in low light, dry eyes, regression, and haloes at night); five of these nine were very negative about their refractive surgery. Seven patients (6.7%) had a very low QIRC score (37.86 ± 2.13), which included the five who volunteered negative comments and two who did not comment. Three of these patients were still wearing spectacles all day every day and two suffered from significant dry eye [21]. In another study looking at the outcome of LASIK, large improvements in QoL were found in the majority of subjects [7]. Three subjects (4.5%) had decreased QIRC scores and these were associated with complications. All reported decreased quality of vision including driving at night, and one reported light sensitivity. Low scores were manifested in visual function, symptoms, concerns, and well-being items. None of the patients with improved QIRC scores experienced any serious complications after LASIK.

2.4.2 RSVP

Schein et al. investigated laser refractive surgery outcomes using the RSVP and found a worsening of overall score in 4.5% of patients [9]. With regard to individual subscales, poorer postoperative scores occurred for 29.5% of subjects on the driving subscale, 19.9% for optical problems, 16.3% for glare, 12.7% for symptoms, 7.4% for concern, 5.9% for functioning, and 2.3% having trouble with corrective lenses. A worsening of at least one subscale score was found in 26% of patients, and 15% reported dissatisfaction with vision postoperatively. Increased age at surgery was the strongest predictor of poorer RSVP scores or dissatisfaction with vision. Lane and Waycaster found that the RSVP did not detect any problems in their phakic IOL cohort [22]. Waring et al. found a 3% rate of increased night vision symptoms after topographically guided LASIK [48].

2.4.3 NEI-RQL

McDonnell et al. found QoL, as measured with the NEI-RQL, improved overall after LASIK, but symptoms of glare were significantly worse, and clarity of vision showed no significant change [5]. Schmidt et al. used the NEI-RQL to identify subjective problems of glare, halos, nighttime problems, distorted vision, blurry vision, and discomfort symptoms after LASIK [31]. Pérez-Cambrodí et al. identified visual symptoms after phakic lens implantation which was correlated with photopic contrast sensitivity [33]. Similarly, Iijima et al. found visual symptoms after phakic lens implantation which was correlated with forward light scatter [32]. A number of authors have identified a deterioration of visual symptoms after refractive lens exchanges with implantation of various multifocal intraocular lenses [27, 34, 35].

2.4.4 QoV

McAlinden et al. found that visual symptoms after LASEK were worse at 5 days and 2 weeks after surgery, but normalized by 1 month post-op [41]. This corresponds to the time required for re-epithelialization. This study showed that the QoV was highly sensitive to visual symptoms induced by refractive surgery. Similarly, the QoV has been shown to be highly sensitive to visual symptoms arising from LASIK presbyopic treatments using a hybrid bi-aspheric micro-monovision ablation profile [42]. De Wit et al. showed that the QoV could detect visual symptoms after refractive lens exchange with a multifocal intraocular lens, albeit at extremely low incidence [43]. Maurino et al. also showed the QoV could detect visual symptoms occurring with multifocal IOLs [26].

2.4.5 Outcomes Reported with Other Instruments

In early PRK outcomes research, 77.5% of 173 patients reported improvement in their general QoL, but 16.8% were debilitated by subjective visual symptoms [6]. The only significant preoperative predictor was refractive error – higher preoperative refraction leads to lower satisfaction rates. In another large PRK study, 31.7% of 690 patients reported worsening night vision after surgery, and 30% reported dissatisfaction with night vision [46]. The frequency of each of the reported symptoms was 34.3% for starbursts, 52.4% for halos, and 61.5% for glare from oncoming headlights. For the patients who experienced glare, 55.6% reported that it was more debilitating post PRK. These findings are in contrast to those reported after LASIK.

McGhee et al. reported only 3 of 50 LASIK patients experienced night vision symptoms, and only one reported dissatisfaction or that their QoL was not improved [2]. They also reported that patients who aimed for a residual myopic refraction expressed disappointment with UCVA and that presbyopes experienced suboptimal near vision. However, limitations of this study are that the only content area tested was functioning and no patients had any serious complications. Hill found that only 3 in 200 subjects would not have LASIK again despite 24% reporting worsening night vision and 27% reporting light sensitivity [8]. The 3 individuals cited worsening night vision, presbyopia, and psychological distress as reasons for opting against the intervention. Bailey et al., in a patient satisfaction survey, found 16 of 604 patients were dissatisfied after LASIK, and a high percentage of these reported symptoms were of glare, halos, or starbursts (81.3%) [49]. Those who had surgical enhancement were found to be more likely to experience these symptoms. Additionally, those with increased age, greater corneal toricity, or smaller pupil size were less likely to be satisfied with the intervention.

Lee et al. developed the Myopia Specific Quality of Life Questionnaire which contains 4 domains: visual function, symptoms, social role function, and psychological well-being [47]. They identified eight adverse symptoms that were most frequently reported after LASIK: eye dryness, blurred vision, lowered indoor or night vision, halos, regression, glare, temporary reduction in near vision, and infection. Multivariate analysis showed that patients having more adverse symptoms experienced significantly less improvement in QoL, so they concluded that freedom from adverse effects is one of the most important requirements for achieving excellent outcomes.

2.4.6 Implications

The caveat with the usually high QoL afforded by refractive surgery is the associated risk of complications. Common complications of laser refractive surgery such as loss of contrast vision, loss of best-corrected vision, regression, and dry eye problems are effectively identified by QoL instruments, with patients requiring spectacle or contact lens correction or experiencing severe dry eye faring the worst. Night vision symptoms are common, but these do not necessarily negatively impact QoL. While quality-of-life research has identified some risk factors for poorer outcome, e.g., older age and multiple treatments, this information does not translate into an altered patient selection strategy. While these results suggest that night vision symptoms are less prevalent with LASIK than PRK, there is no evidence that newer laser treatment paradigms provide any QoL benefit compared to older systems. Ongoing evaluation of refractive surgery outcomes using QoL measurement is required to demonstrate the benefits of technological increments.

Take-Home Pearls

- Questionnaires can effectively demonstrate improved QoL from laser refractive surgery.
- Serious complications of refractive surgery lead to markedly reduced quality of life, but minor complications, like night vision disturbances, may not negatively impact QoL.
- Routine evaluation of refractive surgery outcomes should include QoL measurement.
- The ideal QoL instrument for refractive surgery would contain broad content, be developed and validated with Rasch analysis, and have valid linear scoring, e.g., QIRC.

References

1. Waring GO 3rd. Standard graphs for reporting refractive surgery. J Refract Surg. 2000;16:459–66.
2. Mcghee CN, Craig JP, Sachdev N, et al. Functional, psychological, and satisfaction outcomes of laser in situ keratomileusis for high myopia. J Cataract Refract Surg. 2000;26:497–509.
3. Pesudovs K, Garamendi E, Elliott DB. The quality of life impact of refractive correction (QIRC) questionnaire: development and validation. Optom Vis Sci. 2004;81:769–77.
4. Schein OD. The measurement of patient-reported outcomes of refractive surgery: the refractive status and vision profile. Trans Am Ophthalmol Soc. 2000;98:439–69.
5. Mcdonnell PJ, Mangione C, Lee P, et al. Responsiveness of the National Eye Institute refractive error quality of life instrument to surgical correction of refractive error. Ophthalmology. 2003;110:2302–9.
6. Ben-Sira A, Loewenstein A, Lipshitz I, et al. Patient satisfaction after 5.0-mm photorefractive keratectomy for myopia. J Refract Surg. 1997;13:129–34.
7. Garamendi E, Pesudovs K, Elliott DB. Changes in quality of life after laser in situ keratomileusis for myopia. J Cataract Refract Surg. 2005;31:1537–43.
8. Hill JC. An informal satisfaction survey of 200 patients after laser in situ keratomileusis. J Refract Surg. 2002;18:454–9.
9. Schein OD, Vitale S, Cassard SD, et al. Patient outcomes of refractive surgery. The refractive status and vision profile. J Cataract Refract Surg. 2001;27:665–73.
10. Likert RA. A technique for the measurement of attitudes. Arch Psychol. 1932;140:1–55.
11. Mangione CM, Phillips RS, Seddon JM, et al. Development of the "activities of Daily vision scale". A measure of visual functional status. Med Care. 1992;30:1111–26.
12. Pesudovs K, Garamendi E, Keeves JP, et al. The Activities of Daily Vision Scale (ADVS) for cataract surgery outcomes: re-evaluating validity with Rasch analysis. Invest Ophthalmol Vis Sci. 2003;44:2892–9.
13. Khadka J, Mcalinden C, Pesudovs K. Quality assessment of ophthalmic questionnaires: review and recommendations. Optom Vis Sci. 2013;90:720–44.
14. Massof RW. The measurement of vision disability. Optom Vis Sci. 2002;79:516–52.
15. Waring G, Dougherty PJ, Chayet A, et al. Topographically guided LASIK for myopia using the Nidek CXII customized aspheric treatment zone (CATz). Trans Am Ophthalmol Soc. 2007;105:240–6. discussion 247-248
16. Wright BD, Masters GN. Rating scale analysis. Chicago: MESA Press; 1982.
17. Ang M, Ho H, Fenwick E, et al. Vision-related quality of life and visual outcomes after small-incision lenticule extraction and laser in situ keratomileusis. J Cataract Refract Surg. 2015;41:2136–44.
18. Ieong A, Hau SC, Rubin GS, et al. Quality of life in high myopia before and after implantable Collamer lens implantation. Ophthalmology. 2010;117:2295–300.
19. Meidani A, Tzavara C, Dimitrakaki C, et al. Femtosecond laser-assisted LASIK improves quality of life. J Refract Surg. 2012;28:319–26.
20. Mcalinden C, Pesudovs K, Moore JE. The development of an instrument to measure quality of vision: the quality of vision (QoV) questionnaire. Invest Ophthalmol Vis Sci. 2010;51:5537–45.
21. Pesudovs K, Garamendi E, Elliott DB. A quality of life comparison of people wearing spectacles or contact lenses or having undergone refractive surgery. J Refract Surg. 2006;22:19–27.
22. Lane SS, Waycaster C. Correction of high myopia with a phakic intraocular lens: interim analysis of clinical and patient-reported outcomes. J Cataract Refract Surg. 2011;37:1426–33.
23. Garamendi E, Pesudovs K, Stevens MJ, et al. The refractive status and vision profile: evaluation of psychometric properties and comparison of Rasch and summated Likert-scaling. Vis Res. 2006;46:1375–83.
24. Gothwal VK, Wright TA, Elliott DB, et al. The refractive status and vision profile: Rasch analysis of subscale validity. J Refract Surg. 2010;26:912–5.
25. Berry S, Mangione CM, Lindblad AS, et al. Development of the National eye Institute refractive error correction quality of life questionnaire: focus groups. Ophthalmology. 2003;110:2285–91.
26. Hays RD, Mangione CM, Ellwein L, et al. Psychometric properties of the National eye Institute-refractive error quality of life instrument. Ophthalmology. 2003;110:2292–301.
27. Queiros A, Villa-Collar C, Gutierrez AR, et al. Quality of life of myopic subjects with different methods of visual correction using the NEI RQL-42 questionnaire. Eye Contact Lens. 2012;38:116–21.
28. Shams N, Mobaraki H, Kamali M, et al. Comparison of quality of life between myopic patients with spectacles and contact lenses, and patients who have undergone refractive surgery. J Curr Ophthalmol. 2015;27:32–6.
29. Nehls SM, Ghoghawala SY, Hwang FS, et al. Patient satisfaction and clinical outcomes with laser refractive surgery performed by surgeons in training. J Cataract Refract Surg. 2014;40:1131–8.
30. Nichols JJ, Twa MD, Mitchell GL. Sensitivity of the National Eye Institute refractive error quality of life instrument to refractive surgery outcomes. J Cataract Refract Surg. 2005;31:2313–8.
31. Schmidt GW, Yoon M, Mcgwin G, et al. Evaluation of the relationship between ablation diameter, pupil size, and visual function with vision-specific quality-of-life measures after laser in situ keratomileusis. Arch Ophthalmol. 2007;125:1037–42.
32. Iijima A, Shimizu K, Yamagishi M, et al. Assessment of subjective intraocular forward scattering and quality of vision after posterior chamber phakic intraocular lens with a central hole (hole ICL) implantation. Acta Ophthalmol. 2016;94:e716–20.
33. Perez-Cambrodi RJ, Blanes-Mompo FJ, Garcia-Lazaro S, et al. Visual and optical performance and quality of life after implantation of posterior chamber phakic intraocular lens. Graefes Arch Clin Exp Ophthalmol. 2013;251:331–40.
34. Blaylock JF, Si Z, Aitchison S, et al. Visual function and change in quality of life after bilateral refractive lens exchange with the ReSTOR multifocal intraocular lens. J Refract Surg. 2008;24:265–73.
35. Cillino G, Casuccio A, Pasti M, et al. Working-age cataract patients: visual results, reading performance, and quality of life with three diffractive multifocal intraocular lenses. Ophthalmology. 2014;121:34–44.

36. Mastropasqua R, Pedrotti E, Passilongo M, et al. Long-term visual function and patient satisfaction after bilateral implantation and combination of two similar multifocal IOLs. J Refract Surg. 2015;31:308–14.
37. Labiris G, Gkika MG, Giarmoukakis A, et al. Psychometric properties of the Greek NEI-RQL-42. Eur J Ophthalmol. 2012;22: 466–76.
38. Mcalinden C, Skiadaresi E, Moore J, et al. Subscale assessment of the NEI-RQL-42 questionnaire with Rasch analysis. Invest Ophthalmol Vis Sci. 2011;52:5685–94.
39. Mcalinden C, Skiadaresi E, Gatinel D, et al. The quality of vision questionnaire: subscale interchangeability. Optom Vis Sci. 2013;90:760–4.
40. Solomon KD, Fernandez De Castro LE, Sandoval HP, et al. LASIK world literature review: quality of life and patient satisfaction. Ophthalmology. 2009;116:691–701.
41. Mcalinden C, Skiadaresi E, Pesudovs K, et al. Quality of vision after myopic and hyperopic laser-assisted subepithelial keratectomy. J Cataract Refract Surg. 2011;37:1097–100.
42. Luger MH, Mcalinden C, Buckhurst PJ, et al. Presbyopic LASIK using hybrid bi-aspheric micro-monovision ablation profile for presbyopic corneal treatments. Am J Ophthalmol. 2015;160: 493–505.
43. De Wit DW, Diaz JM, Moore TC, et al. Refractive lens exchange for a multifocal intraocular lens with a surface-embedded near section in mild to moderate anisometropic amblyopic patients. J Cataract Refract Surg. 2012;38:1796–801.
44. Maurino V, Allan BD, Rubin GS, et al. Quality of vision after bilateral multifocal intraocular lens implantation: a randomized trial--AT LISA 809M versus AcrySof ReSTOR SN6AD1. Ophthalmology. 2015;122:700–10.
45. Skiadaresi E, Mcalinden C, Pesudovs K, et al. Subjective quality of vision before and after cataract surgery. Arch Ophthalmol. 2012;130:1377–82.
46. Brunette I, Gresset J, Boivin JF, et al. Functional outcome and satisfaction after photorefractive keratectomy. Part 2: survey of 690 patients. Ophthalmology. 2000;107:1790–6.
47. Lee J, Park K, Cho W, et al. Assessing the value of laser in situ keratomileusis by patient-reported outcomes using quality of life assessment. J Refract Surg. 2005;21:59–71.
48. Awwad ST, Alvarez-Chedzoy N, Bowman RW, et al. Quality of life changes after myopic wavefront-guided laser in situ keratomileusis. Eye Contact Lens. 2009;35:128–32.
49. Bailey MD, Mitchell GL, Dhaliwal DK, et al. Patient satisfaction and visual symptoms after laser in situ keratomileusis. Ophthalmology. 2003;110:1371–8.

Part II

LASIK Intraoperative Complications

Thin, Irregular, Buttonhole Flaps

3

O. Bennett Walton and Stephen G. Slade

Core Messages

- A thin, irregular, or buttonhole flap is a significant complication of lamellar surgery that typically calls for aborting the case.
- Thin, irregular, or buttonhole flaps can occur with both femtosecond lasers and microkeratomes.
- The cause of a thin, irregular, or buttonhole flap is often unclear and can be multifactorial.
- Causes of a thin, irregular, or buttonhole flap may include low pressure, loss of suction, poor applanation, poor corneal lubrication, preexisting corneal pathology, poor metal blade quality, or keratome malfunction.
- Most thin, irregular, or buttonhole flap cases can be reperformed at a later date with either LASIK or PRK and do have a good prognosis.
- The key to successful management is to avoid ablation and avoid femtosecond flap lift.

3.1 Introduction

Many of the serious complications of LASIK are related to flap creation. Fortunately, as femtosecond lasers have replaced microkeratomes in many areas, these complications are becoming less frequent. In this chapter, we will look at the causes, prevention, diagnosis, and treatment of thin, irregular, or buttonhole flaps of poor quality. The incidence of buttonhole flaps using a mechanical microkeratome ranges between 0.06 and 2.6% of general LASIK procedures [1–3]. The main incidence of femtosecond laser buttonhole flaps, gas breakthrough, seems less frequent than mechanical keratome causes. The occurrence of a buttonhole flap is the most likely to result in a poor refractive outcome if not managed properly (Fig. 3.1).

3.2 Causes

Complications due to poor keratectomy can cause major visual problems. Keratectomies can be incomplete, decentered, or uneven. Steep corneas are associated with buttonhole flaps, and flat corneas are associated with free caps. An incomplete keratectomy is usually caused by a suction break. It is critical to have good suction for the duration of the laser activity or keratome pass. If the dissection stops before the pass is complete, there might not be room to place the ablation. The keratectomy can be extended by hand but will not be of the same quality. An irregular or damaged blade can cause a grossly irregular keratectomy.

During creation of the femtosecond corneal flap, dissection is only complete after the flap is manually loosened and lifted. Because the flap isn't complete until lifted, complications may occur during lift if there are areas of opaque bubble layer or irregular adhesion. These can rarely lead to a defect similar to a "buttonhole" or "donut-shaped" flap that can occur with a mechanical keratectomy. The buttonhole flap can also be created when the focus of the laser beam begins the cut at the desired depth in the stroma but features gas breakthrough anterior to the epithelium and then returns back to the stroma. Buttonhole flaps can be associated with one or more of the following factors in femtosecond procedures:

1. Attempted creation of very thin corneal flap (<100 μm)
2. Poor applanation with contact glass
3. Patient movement during the procedure

In summary, poor quality flaps can be associated with one or more of the following factors in flap creation:

1. Loss of suction during the cut
2. Patient cornea steeper than 46.00 D prior to surgery [4]
3. Low or reduction in patient intraocular pressure [5]

O.B. Walton, M.D., M.B.A. (✉) • S.G. Slade, M.D., F.A.C.S.
Slade & Baker Vision, 3900 Essex Ln, Suite 101,
Houston, TX 77027, USA
e-mail: drwalton@visiontexas.com

J.L. Alio, D.T. Azar (eds.), *Management of Complications in Refractive Surgery*,
https://doi.org/10.1007/978-3-319-60561-6_3

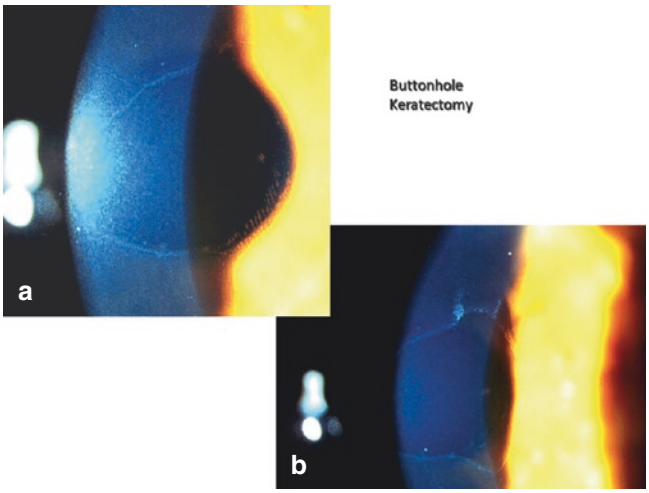

Fig. 3.1 In these two pictures of the same cornea, a microkeratome cut only the outer portion of the flap, leaving the central zone unaffected. Lifting and ablating is not advised in the case of incomplete flaps, whether due to microkeratome buttonhole or centrally incomplete femtosecond treatment (Courtesy of Stephen G. Slade, MD)

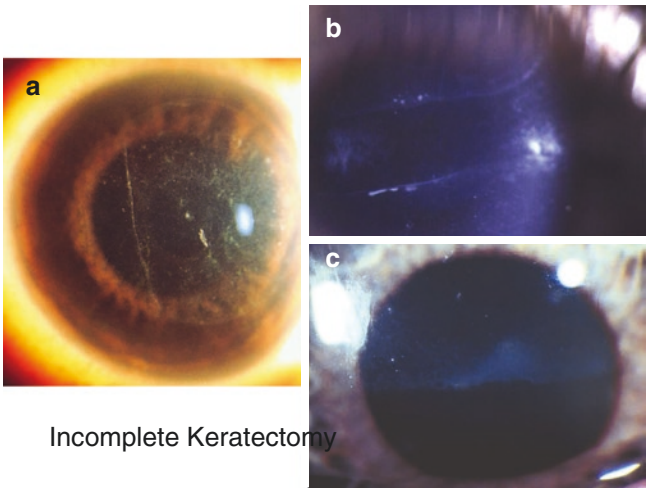

Fig. 3.2 Three incomplete flaps are shown: (**a**) partial flap with the hinge in the pupil space, (**b**) a strip of uncut cornea directly over the visual axis caused by debris on the microkeratome blade, and (**c**) a hemi flap with the entire bottom half of the cornea uncut due to a damaged blade. Excessive fluid, meibom or other optical media interruption can result in a similar finding with a femtosecond laser. Lifting and ablating is not advised after an incomplete keratectomy (Courtesy of Stephen G. Slade, MD)

4. Poor lubrication of the corneal surface or keratome malfunction
5. Excess tissue being compressed beyond applanation by a keratome foot plate, causing buckling of the cornea [6]

3.3 Diagnosis

A poor quality flap should be suspected whenever the visualized laser pattern or keratome cut does not proceed as expected. A buttonhole or thin flap often can be seen without manipulating the flap at all. Sometimes allowing the corneal surface to dry slightly or wiping off the tear film will reveal the edges of a buttonhole, for example. If the diagnosis is uncertain, carefully inspect the flap. Always use caution in lifting such a flap. Buttonhole flaps can be incomplete with a continuous layer of epithelium overlying the hole in Bowman's.

One advantage of diagnosing a poor quality flap with the femtosecond laser is that a poor quality flap can often be seen during its creation as discussed below (Fig. 3.2).

3.4 Prevention

The inspection, setup, and preoperative testing or calibration of these instruments is critical. Careful attention to minute details is essential to minimize and avoid potential complications, as well as to obtain an excellent flap. Exposure is also vital to the keratectomy. This is largely dependent on orbital anatomy. The deep-set eye with an overhanging brow is best avoided in the early cases. Proper anesthesia and sedation will aid in achieving good exposure. The main goal is to provide a stable suction and applanation, with clear path and gear track for microkeratomes. Fluid management is important in both femtosecond and microkeratome use, in the former to ensure good corneal or limbal suction and in the latter to avoid a false meniscus in the measurement of the cap diameter and IOP. The cornea should be a little dry for the applanation yet wet for a microkeratome pass. Always take a moment to inspect the eye before the placement of the suction ring. There should be no chemosis and the pupil should be centered between the speculum. A speculum that provides maximum exposure with reasonable patient comfort is desirable. If chemosis is present, the fluid should be milked down beneath the lid speculum. The pupil should be constricted only with the light from the microscope. As with any surgery, the success of each step is dependent on the success of the preceding step. Positioning, exposure, and stable suction are crucial to either type of successful flap creation. At this point, laser may be fired, or a carefully inspected microkeratome with a sharp, accurate blade with a slow, controlled pass may be used. Of note, there appears to be evidence that second eyes in consecutive microkeratome treatment may be at higher risk, [2] and this may be explained by differential blade sharpness between in the two passes.

The femtosecond laser offers a unique advantage to the prevention of complications from poor quality flaps. Quite often a poor quality flap can be actually detected during the creation of the flap with a femtosecond laser. This is because the flap is visible at all times during the procedure. With experience, a thin flap or buttonhole flap with gas breakthrough can be seen in its creation and the procedure stopped. More commonly, risks of variable adhesion in the bed may be noted by the presence of opaque bubble layer during the femtosecond treatment. Additionally, while not a flap quality issue, femtosecond flaps 90 microns or thinner had a higher incidence of postoperative haze than 100 micron flaps [7].

Of course avoidance and awareness of patients at risk are the best way to prevent flap complications. Patients with the following conditions may be more prone to experiencing flap quality complications:

- History of collagen vascular disease
- Patient cornea steeper than 46.00 D prior to surgery
- Conjunctival scarring after prior ocular surgery
- Previous incisional keratotomy
- Prior ocular, specifically cornea injury
- History of keratoconus
- Previous scleral buckling surgery
- Patient with unusually thick epithelial layer (>90 μm)

3.5 Treatment

Clinical concerns when dealing with poor quality flaps include the potential for epithelial cells to infiltrate the interface, causing epithelial ingrowth in the central axis. This may result in corneal scarring in the visual field, affecting visual acuity. Worse, invasive epithelial ingrowth can lead to stromal melt.

If a keratectomy has an irregular surface, there is an important and simple safety feature of lamellar surgery that should not be forgotten. No matter how irregular the surface of the bed might be, there is a perfect match in the underside of the flap. Therefore, if the flap is simply replaced, the patient will usually return to the preoperative refraction and best corrected vision by the next morning. The femtosecond laser is even more forgiving in this regard, in that the flap is held in place by the micro tissue bridges of uncut stroma. These tags hold the flap in place so that once the diagnosis is made, since the flap is securely attached, there is plenty of time to wait until a retreatment is advisable. An additional advantage is that the epithelium and Bowman's are cut last with a femtosecond laser and so the procedure may be aborted prior to the vertical cut, leaving epithelium and Bowman's intact. In cases of partial flaps without buttonhole or gas escape, if a recut is ever attempted with a laser, keeping the same patient interface is crucial for achieving the same depth. Raster patterns are more forgiving, as dissection can be started from the distal, single-cut end of the flap to avoid accidentally ending up in the dead-end partial cut. Problems are created when an irregular bed is altered with an attempted ablation that no longer matches the flap. This is also important to remember with incomplete resections. When in doubt, put the flap back and do not ablate. One of the more pleasant features of lamellar surgery is that the eye can be essentially back to the preoperative shape and clarity the next day and then reoperated on in the next few weeks or months depending on the situation. If an incomplete resection is present, and there is room for the ablation, one can proceed.

With resections that stop short of the needed diameter, surgeons have extended the flap by hand, but this is dangerous and will not give as smooth as a surface as the microkeratome. Remember that incomplete resections can also be caused by a blade that has been damaged, dulling the cutting edge so that a vertically incomplete resection is produced. With severe suction breaks and very small eccentric resections, never attempt to ablate; just try to replace the cap as best as possible (Fig. 3.3).

Ablation of an eye with a buttonhole flap at the time of primary surgery has been associated with a loss of best corrected acuity and must be avoided [2]. If it is apparent during the femtosecond cut itself that a buttonhole is forming, then the procedure should be terminated at once (Fig. 3.4). The advantage of the femtosecond laser in this situation is that the epithelium will remain uncut and the potential flap undisturbed. In this case, the flap should not be lifted or explored. In order to minimize epithelial ingrowth, some surgeons prefer to remove the epithelium from the central button or island of Bowman's layer [8]. Again, *ablation should not be performed under the flap*. There have been reports of immediate phototherapeutic keratectomy for epithelial removal with photorefractive keratectomy treatment with mitomycin C [9]. In such cases, haze is considered a risk, and it is strongly recommended that the ablation depths be carefully checked before such cases to ensure that there is either no significant flap left or enough to lie stably on the stroma. Leaving an ultrathin and irregular flap after surface ablation of a buttonhole is not advised, and either PRK or a repeated LASIK can always be attempted later with a more stable cornea than at the time of the initial buttonhole flap creation. Usually, a bandage lens is placed over the buttonhole flap. A deeper flap may be recut (20–60 μm deeper) approximately 3–6 months later, once best corrected visual acuity returns and the refraction is stable. Some surgeons advocate scraping the epithelium and performing PRK laser ablation. However, this procedure is subject to the risk of haze for higher ablations [10].

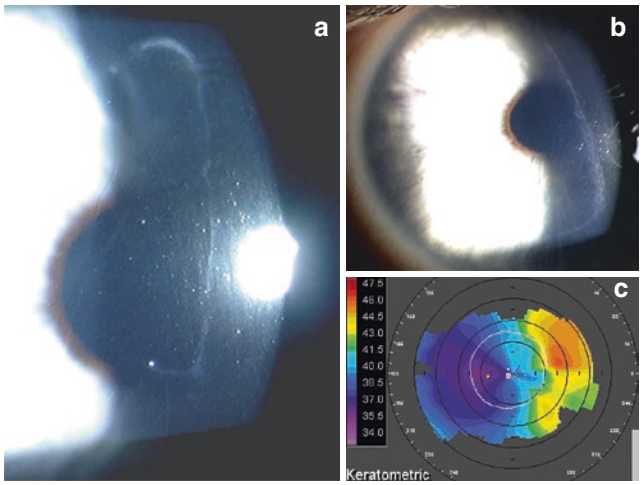

Fig. 3.3 Incomplete flaps (**a, b**) that were misguidedly lifted and ablated. Keratometry (**c**) shows that nearly half the cornea received none of the intended myopic ablation, whereas the the flat area was doubly flattened because the stromal side of the flap had shielded the untreated area and received that treatment (Courtesy of Stephen G. Slade, MD)



Fig. 3.4 Vertical gas breakthrough in femtosecond flap creation. This is effectively a buttonhole, and it would not be recommended to lift this flap (Courtesy Perry S. Binder MS, MD)

Take-Home Pearls

- The refractive surgeon is advised to.
- Identify patients at risk for flap complications.
- Carefully set up and review your microkeratome, laser, and surgical protocol.
- Be aware of these complications and suspect them in any uncertain situation.
- Do not ablate a poor quality bed.

References

1. Leung ATS, Rao SK, Cheng ACK, Yu EWY, Fan DSP, Lam DSC. Pathogenesis and management of laser in situ keratomileusis flap buttonhole. J Cataract Refract Surg. 2000;26:359.
2. Lichter H, Stulting R, Waring G III, Russell G, Carr J. Buttonholes during LASIK: etiology and outcome. J Refract Surg. 2007;23(5):472–6.
3. Jain V, Mhatre K, Shome D. Flap buttonhole in thin-flap laser in situ keratomileusis: case series and review. Cornea. 2010;29(6):655–8.
4. Ambrosio R Jr, Wilson SE. Complications of laser in situ keratomileusis: etiology, prevention, and treatment. J Refract Surg. 2001;17:356.
5. Wu HK, Allam WA. Incomplete LASIK Flap: in J. L. Alió, D. T. Azar (eds.). Management of Complications in Refractive Surgery, Springer London. 2008. pp. 19–21.
6. Gimbel HV, Anderson Penno EE, van Westenbrugge JA, Ferensowicz M, Furlong MT. Incidence and management of intraoperative and early postoperative complications in 1000 consecutive laser in situ keratomileusis cases. Ophthalmology. 1998;105(10):1845.
7. Rocha K, Kagan R, Smith S, Krueger R. Thresholds for interface haze formation after thin-flap femtosecond laser in situ keratomileusis for myopia. Am J Ophthalmol. 2009;147(6):966–72.
8. Updegraff SA, Kritzinger MS. Laser in situ keratomileusis technique. Curr Opin Ophthalmol. 2000;11:271–2.
9. Kymionis G, Portaliou D, Karavitaki A, Krasia M, Kontadakis G, Stratos A, Yoo S. LASIK flap buttonhole treated immediately by PRK with mitomycin C. J Refract Surg. 2010;26:225–8.
10. Melki SA, Azar DT. LASIK complications: etiology, management, and prevention. Surv Ophthalmol. 2001;46(2):97.

Further Reading

Ambrosio R Jr, Wilson SE. Complications of laser in situ keratomileusis: etiology, prevention, and treatment. J Refract Surg. 2001;17:350–79.

Gimbel HV, Basti S, Kaye GB, Ferensowicz M. Experience during the learning curve of laser in situ keratomileusis. J Cataract Refract Surg. 1996;22:542–50.

Gimbel HV, Penno EE, van Westenbrugge JA, Ferensowicz M, Furlong MT. Incidence and management of intraoperative and early postoperative complications in 1000 consecutive laser in situ keratomileusis cases. Ophthalmology. 1998;105(10):1839–47.

Grupcheva CN, Malik TY, Craig JP, McGhee CNJ. In vivo confocal microscopy of corneal epithelial ingrowth through a laser in situ keratomileusis flap buttonhole. J Cataract Refract Surg. 2001;27:1318–22.

Iskander NG, Timothy Peters N, Penno EA, Gimbel HV. Postoperative complications in laser in situ keratomileusis. Curr Opin Ophthalmol. 2000;11:273–9.

Jacobs JM, Taravella MJ. Incidence of intraoperative flap complications in laser in situ keratomileusis. J Cataract Refract Surg. 2002;28:23–8.

Jain V, Mhatre K, Shome D. Flap buttonhole in thin-flap laser insitu keratomileusis: case series and review. Cornea. 2010;29(6):655–8.

Kymionis G, Portaliou D, Karavitaki A, Krasia M, Kontadakis G, Stratos A, Yoo S. LASIK flap buttonhole treated immediately by PRK with mitomycin C. J Refract Surg. 2010;26:225–8.

Lam DSC, Leung ATS, Wu JT, Cheng ACK, Fan DSP, Rao SK, Talamo JH, Carmen Barraquer C. Management of severe flap wrinkling or dislodgement after laser in situ keratomileusis. J Cataract Refract Surg. 1999;25:1441–7.

Lam DSC, Cheng ACK, Leung ATS. Letter to the editor. Ophthalmology. 1999;106(8):1455–6.

Leung ATS, Rao SK, Cheng ACK, Yu EWY, Fan DSP, Lam DSC. Pathogenesis and management of laser in situ keratomileusis flap buttonhole. J Cataract Refract Surg. 2000;26:358–62.

Lichter H, Stulting R, Waring G III, Russell G, Carr J. Buttonholes during LASIK: etiology and outcome. J Refract Surg. 2007;23(5):472–6.

Marinho A, Pinto MC, Pinto R, et al. LASIK for high myopia. Ophthalmic Surg Lasers. 1996;27(suppl):S517–20. Bas AM, Onnis R. Excimer laser in situ keratomileusis for myopia. J Refract Surg 1995; 11(suppl): S229

Melki SA, Azar DT. LASIK complications: etiology, management, and prevention. Surv Ophthalmol. 2001;46(2):95–116.

Penno EA, Kaye G, Van Westenbrugge J, Gimbel HV. Letter to the editor. Ophthalmology. 1999;106(8):1456–7.

Review of MAUDE database reports on buttonhole flaps for period 1992–2006.

Rocha K, Kagan R, Smith S, Krueger R. Thresholds for interface haze formation after thin-flap femtosecond laser in situ keratomileusis for myopia. Am J Ophthalmol. 2009;147(6):966–72.

Stulting RD, Carr JD, Thompson KP, Waring GO III, Wiley WM, Walker JG. Complications of laser in situ keratomileusis for the correction of myopia. Ophthalmology. 1999;106(1):13–20.

Tham VM, Maloney RK. Microkeratome complications of laser in situ Keratomileusis. Ophthalmology. 2000;107(5):920–4.

Updegraff SA, Kritzinger MS. Laser in situ keratomileusis technique. Curr Opin Ophthalmol. 2000;11:267–72.

Wilson SE. LASIK: management of common complications. Cornea. 1998;17(5):459–67.

4 Intraoperative Flap Complications in LASIK: Prevention and Management of Free Flaps

Mauro Tiveron Jr. and Jorge L. Alió

Core Messages

- Free cap is a flap which lacks the hinge that attaches it to the cornea.
- This complication is closely linked with the use of microkeratomes for flap creation.
- Prevention of free flaps in microkeratome-assisted LASIK surgery is critical.
- Careful inspection of the corneal marks assists flap repositioning.
- Management of free flap without corneal marks is possible.

4.1 Definition of Free Flap

A flap which lacks the hinge that attaches it to the cornea is defined as a free flap or cap. Free flaps result by shallow engagement of the keratome on the corneal surface due to a loss of suction during the microkeratome pass, allowing the blade to skim the top of the cornea [1].

More than a complication, a free flap should be considered an inconvenience that slows up the procedure and forces the surgeon to manage the flap more delicately and meticulously. In addition, this inconvenience can become a serious complication when the corneal marks have not been performed before the flap cutting or in case of a flap loss.

M. Tiveron Jr., M.D. • J.L. Alió, M.D., Ph.D., F.E.B.O. (✉)
Vissum, Instituto Oftalmológico Alicante,
Avda. de Denia s/n, 03016 Alicante, Spain

Universidad Miguel Hernandez, Alicante, Spain
e-mail: jlalio@vissum.com

4.2 Frequency and Etiology of Free Flap

The incidence of free flap ranges from 0.7% to 5.9% [2]. Lin and Maloney reported a free flap incidence of 1% in a retrospective study using the Automated Corneal Shaper microkeratome, and the incidence of this complication was lower using the Hansatome microkeratome as reported by Walker and Wilson [3]. The incidence of free flap with a mechanical microkeratome was reported to be up to 10% [4], although this varies in the literature depending on the microkeratome type and surgeon experience.

This flap complication mainly results from low intraoperative intraocular pressure and large flat corneas with an average keratometric power of <41 diopters. The low intraoperative pressure in this situation is known as "pseudosuction," affecting flap creation by the occlusion of the suction port other than at the globe and generally producing a very thin flap. Pseudosuction is when the vacuum registers high because the conjunctiva or drapes are occluding the suction holes. In this case, the intraocular pressure will not be sufficiently elevated to pass the microkeratome [5].

In cases of flatter preoperative keratometry, a small corneal area exposes through the ring, and then the blade engages late in its passage across the cornea and exits early, increasing the incidence of a free cap.

4.3 Prevention of Free Flap in LASIK Surgery

The prevention of free flaps using microkeratome is not always possible. However, to avoid free flaps with this device, the surgeon should complete the following checks before cutting the flap: (1) perform adequate corneal marks preoperatively, (2) ensure the suction ring has a firm grasp of the eye, (3) confirm that the intraocular pressure has risen, and (4) confirm that the patient's vision has decreased [6].

J.L. Alio, D.T. Azar (eds.), *Management of Complications in Refractive Surgery*,
https://doi.org/10.1007/978-3-319-60561-6_4

Adequate corneal marks must be performed preoperatively by making asymmetrical marks that clearly cross the sclerocorneal limbus to avoid improper orientation (Fig. 4.1). When the flap is repositioned inversely (epithelium vs. stroma), distinguishable non-coinciding marks are observed between the flap and the peripheral cornea (Fig. 4.2).

Making corneal marks with different sized circles or by using asymmetrical linear marks, one more central and the other more peripheral, ensures that the edge of the flap will be crossed by one of them. These marks can aid in the alignment with proper orientation if a free flap occurs.

As it is not radial, the landmark forms a distinguishable non-coincident mirror image when the flap is repositioned inversely (epithelium vs. stroma).

A flat keratometry reading on the preoperative cornea should be factored into preoperative planning due to higher incidence of free flaps and thin flaps. Thus, in flat corneas, the corneal marks are still more important to prevent further complications in case of a free cap.

The femtosecond laser technology for LASIK surgery may prevent free flap. Moreover, the flap performed by femtosecond laser is safer and more predictable, even in preventing other complications related to the flap-cutting process [7].

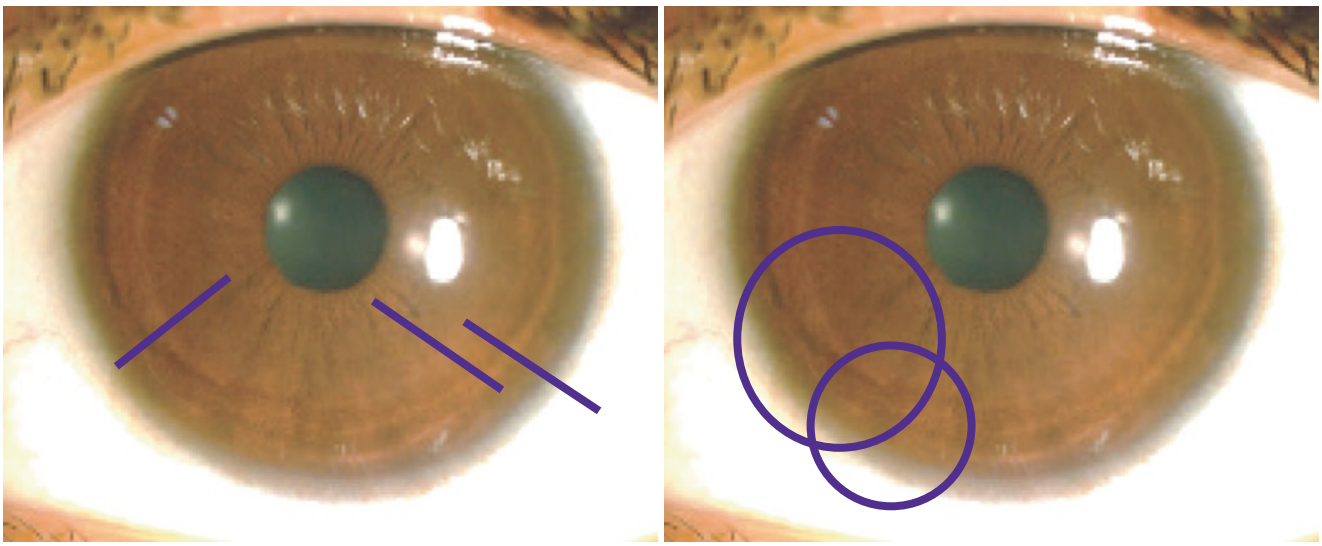

Fig. 4.1 Making corneal marks with different sized *circles* or by using asymmetrical linear marks, one more central and the other more peripheral, guarantees us that, in any case, the edge of the flap will be crossed by one of them. These marks can aid in the alignment with proper orientation if a free flap occurs

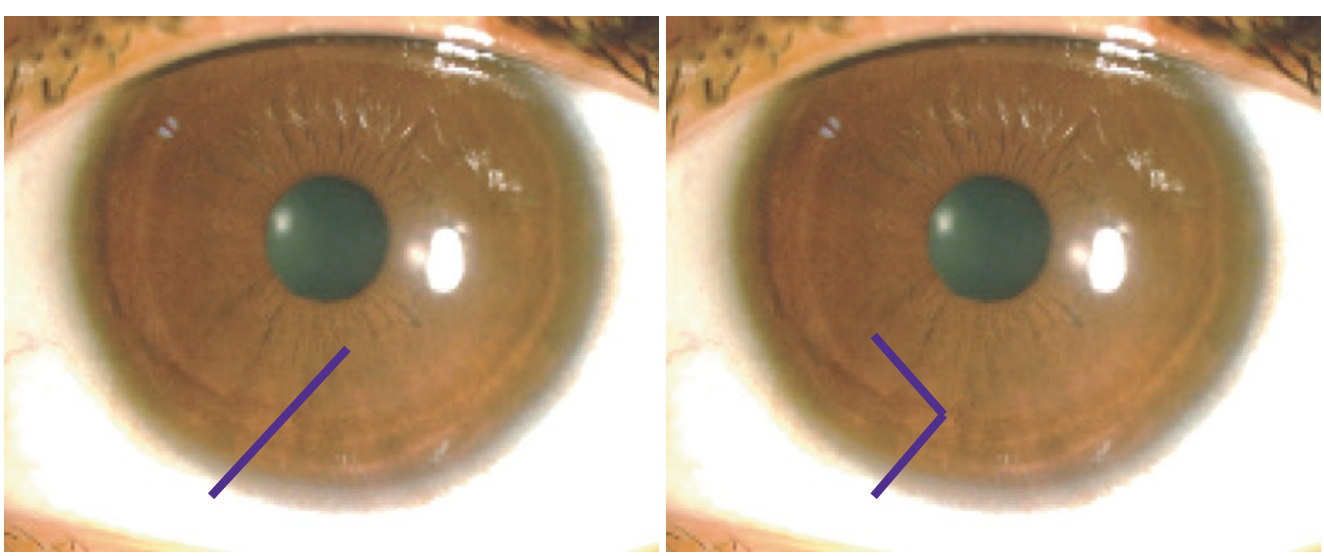

Fig. 4.2 As it is not radial, the landmark forms a distinguishable non-coincident mirror image when the flap is repositioned inversely (epithelium vs. stroma)

4.4 Intraoperative Assessment and Handling the Problem

In the majority of free flaps, the cap is recovered from the blade platform of the microkeratome. In account of this, the corneal marks preoperatively are essential to better manage the problem and allow it to be repositioned in the proper direction.

During excimer laser ablation, the cap should be kept covered in the microkeratome or carefully protected with a moist Merocel sponge. The next adequate management approach involves inspection of the surgical marks and correctly replacing the free cap on the stromal bed to obtain the best realignment. It is imperative to replace the cap stromal surface down. After a period of 3–5 min of air drying, the placement of therapeutic contact lenses is recommended for 48 h to protect the flap from the eyelids and to promote adherence to the stromal bed. Other methods for securing free flaps include running or interrupted sutures with 10-0 monofilament nylon, but usually they are not necessary to keep the cap in place [6, 8, 9].

4.5 Management of Free Flap Without Corneal Marks

If a free cap is created without marks, the cap should be carefully replaced over the stromal bed. After adequate air drying or sutures on the flap, a therapeutic contact lens must be placed to avoid a flap loss. In this situation, it is recommended to cancel the laser ablation and after at least 3 months of healing, the surgeon can consider a retreatment to reach a better final visual outcome [10, 11].

Some of the potential complications associated with such cases include irregular astigmatism, recurrent flap dislodgement, epithelial ingrowth, interface deposits, and flap loss.

4.5.1 Free Flap Rotational Study

According to Baviera J [12], theoretically, a free flap has parallel faces that are the result of a perfect cut leaving a flap with a uniform thickness. If this were 100% true, there would be no optical effects. The rotation of the flap would be similar to the rotation on the eye of a therapeutic contact lens with neutral dioptric power. However, it is virtually impossible to obtain a flap with these characteristics. The flap is usually thinner at the beginning and gradually becomes thicker at the center as the microkeratome advances.

Therefore, if we suppose that the flap once again becomes thinner at the end of the cut, when the blade leaves the eye, we will obtain a flap that behaves optically like a plus-power cylindrical lens, with its axis at 90° and power at 0° (microkeratome pass along the 0–180° axis). Logically, the resulting corneal bed would be the negative image of the flap and would behave like a minus-power cylinder of the same power and axis (Fig. 4.3). If the flap was reset in its original position, both cylinders would balance and the optical result would be neutral [13].

An irregular microkeratome cut, leads to a thicker flap in the center and a thinner one at the periphery (plus cylinder). The stromal bed contains the negative image of the flap (minus cylinder).

Now, if, due to loss of the marks, the cylinders do not fit back into their original position, then we have crossed cylinders in which the plus-power cylinder (flap) has rotated on the minus-power cylinder (corneal bed). This results in mixed astigmatism with a neutral spherical equivalent, where the axis and power depend on the angle of rotation and the power of the cylinders by microkeratome cutting.

If we assume that the laser ablation has not induced and has eliminated any preexisting astigmatism, the astigmatism that appears after an undesired rotation of the flap would be a consequence of this bicylindrical effect between the flap and the corneal bed.

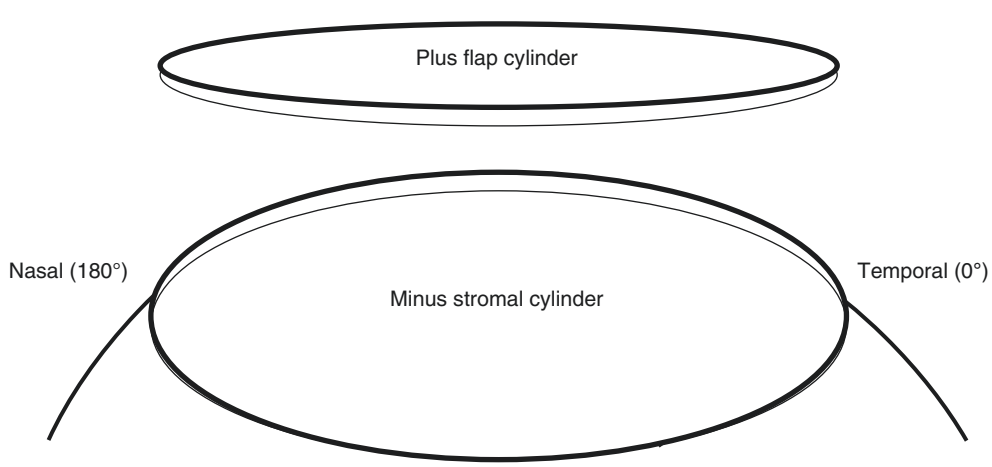

Fig. 4.3 Consequence of an irregular microkeratome cut. This leads to a thicker flap in the center and a thinner one at the periphery (plus cylinder). The stromal bed contains the negative image of the flap (minus cylinder)

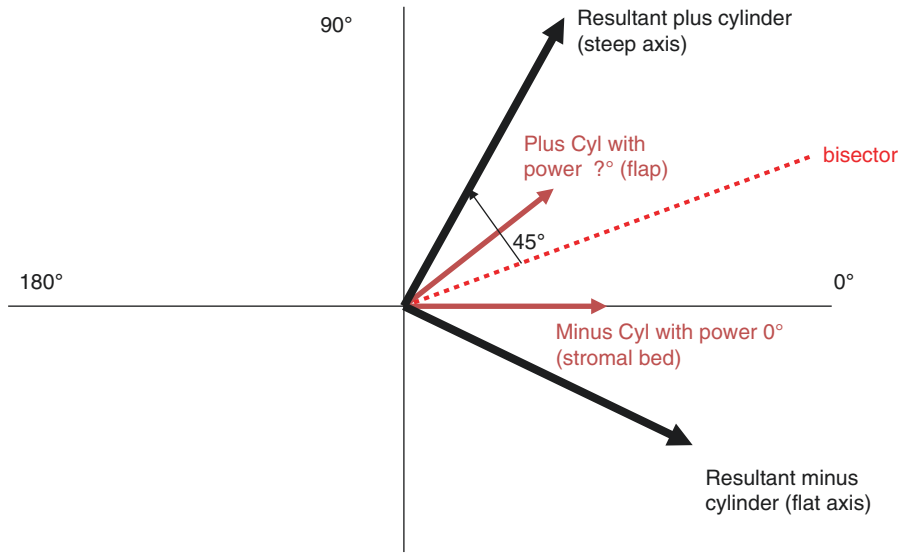

Fig. 4.4 Cross cylinders share the bisector with the flat and steep axes of the mixed astigmatism resulting from the turn of the first two. The resultant plus cylinder (steep axis) is at 45° counterclockwise from the bisector of the two cross cylinders

According to Rubin [14], the bisector of the cylinders that have rotated on one another coincides with the bisector formed between the steep and flat axes of the refractive mixed astigmatism resulting from the rotation. Therefore, the steep axis of the resulting refractive astigmatism would be at 45° counterclockwise of the bisector formed by the two cylinders that have rotated on one another (Fig. 4.4).

Cross cylinders share the bisector with the flat and steep axes of the mixed astigmatism resulting from the turn of the first two. The resultant plus cylinder (steep axis) is at 45° counterclockwise from the bisector of the two cross cylinders.

We could derive the following formula: postoperative axis (in plus cyl) = initial axis (MQ pass) + 45 + angle of flap rotation/2. Thus, flap angle rotation = 2 × postoperative axis − 90.

Then

- If the resulting value of the angle of flap rotation is positive, we would consider the turn clockwise, and if it is negative, counterclockwise.
- If a microkeratome with an up-down cut was used, the initial axis (MQ pass) would not be 0°, but 90°; therefore, the formula would be flap angle rotation = 2 × postoperative axis − 270.

Clinical Cases

Case 1 (loss of corneal marks): For a 34-year-old woman with OS −2.50 sph, VA = 20/20−, LASIK was programmed for emmetropia, and a free flap was obtained on which the marks were erased.

Result at 4 weeks: *−2.50 sph + 4.25 cyl × 15°.*

The following formula was applied: flap angle rotation = 2 × postoperative axis − 90° = 2 × 15 − 90 = −60.

As the sign was negative, the rotation was considered counterclockwise. The patient was taken into the operating room, and after the relevant ink marks were made on the flap, it was lifted and turned 60° counterclockwise with the help of a 360° graduated ring.

Result after 6 weeks: *VA = 20/20−.*

Case 2 (loss of corneal marks): For a 29-year-old man, OD −1.25 sph + 4 cyl × 75°, VA = 20/20. LASIK was programmed for emmetropia, and a free flap was obtained on which the marks were erased.

Result at 5 weeks: *−2.25 sph + 6 cyl × 4, VA = 20/30+.*

The following formula was applied: flap angle rotation = 2 × postoperative axis − 90 = 2 × 4 − 90 = −82. As the sign was negative, rotation was considered counterclockwise. The patient was taken to the operating room, and after the relevant ink marks were made on the flap, it was lifted and turned 82° counterclockwise in the same way as the previous case (Figs. 4.5 and 4.6).

Result: *−0.75 sph + 1 cyl × 96, with improvement in VA to 20/20−.*

Corneal topography shows the inverse astigmatism resulting from incorrect repositioning of the free flap

Topographic appearance after solving the induced astigmatism by lifting and rotating the flap 82° counterclockwise

Case 6 (loss of corneal marks): For a 40-year-old woman, OS with −1.75 sph + 0.25 cyl × 137°, VA = 20/20, LASIK was programmed for emmetropia and resulted in a free flap with loss of marks.

Result at 6 weeks: *−1.25 sph + 2.5 cyl × 57°, VA = 20/25.*

If the following formula had been applied, flap angle rotation = 2 × postoperative axis − 90 = 2 × 57 − 90 = 24, then the flap would have had to be turned 24° clockwise. Nevertheless, the surgeon chose to carry out LASIK enhancement.

Result: *+0.5 cyl × 165°, VA = 20/20−.*

A review of the literature reported three similar cases [13]. All three finished with induced mixed astigmatism accompanied by a reduction in the corrected distance visual acuity. The cases were solved using rotation of the

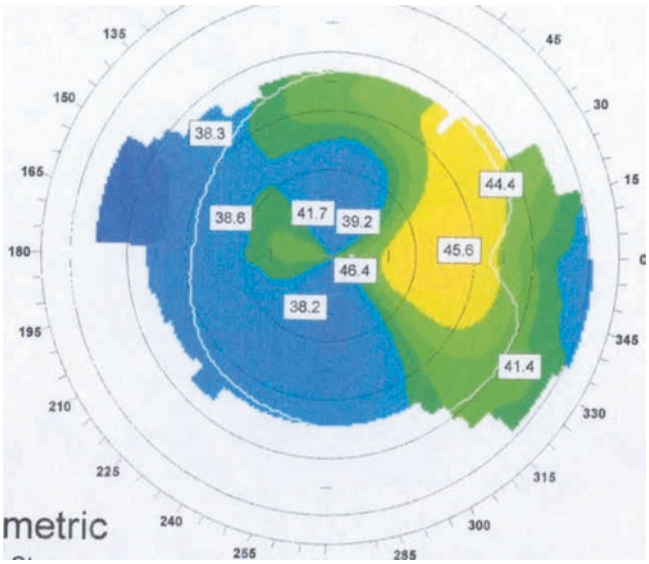

Fig. 4.5 Corneal topography shows the inverse astigmatism resulting from incorrect repositioning of the free flap

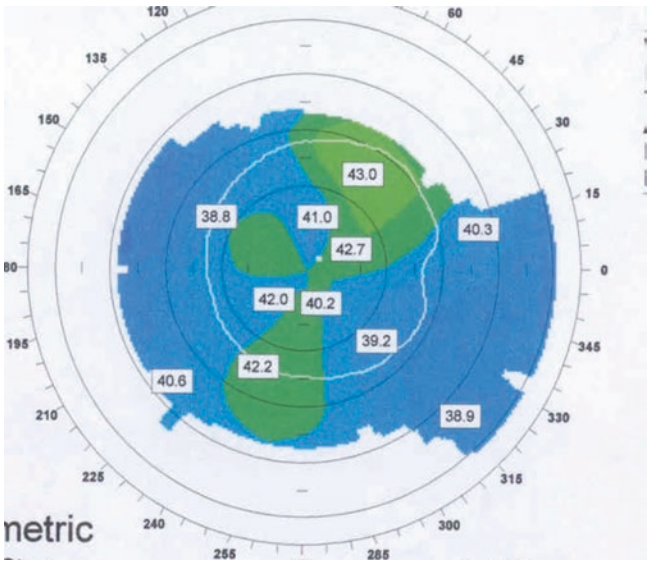

Fig. 4.6 Topographic appearance after solving the induced astigmatism by lifting and rotating the flap 82° counterclockwise

free flap and applying the formula described, although the third case needed a second rotation, which the authors attribute to the fact that the microkeratome did not pass exactly on the usual 0–180° axis.

Take-Home Pearls

- Making asymmetrical marks sufficiently long can aid in alignment with proper orientation if a free flap occurs.
- Non-radial marks that are distinguishable should be made, even when so the flap is repositioned inversely (epithelium vs. stroma).
- If the marks are lost completely, try to reposition the free flap using the epithelial details from the edge of the flap.
- Inadequate repositioning (rotation) leads to mixed astigmatism, generally accompanied by reduced BCVA.
- Astigmatism induced by rotation of the flap can be solved, using the optical genesis of the astigmatism induced by rotation of equal cylinders with opposite signs.
- Always pass the microkeratome on the same axis (0–180° or 90–270°), and then if there is rotation when repositioning the flap, this can be corrected as described.
- The femtosecond laser technology for LASIK surgery is considered the best prevention for free flap.

References

1. Stulting RD, Carr JD, Thompson KP, Waring GO 3rd, Wiley WM, Walker JG. Complications of laser in situ keratomileusis for the correction of myopia. Ophthalmology. 1999;106:13–20.
2. Lin RT, Maloney RK. Flap complications associated with lamellar refractive surgery. Am J Ophthalmol. 1999;127:129–36.
3. Walker MB, Wilson SE. Lower intraoperative flap complication rate with the Hansatome microkeratome compared to Automated Corneal Shaper. J Cataract Refract Surg. 2000;26:79–82.
4. Barraquer JI. Generalidades sobre las técnicas quirúrgicas actuales. In: Barraquer JI, editor. Queratomileusis y Queratofaquia. Bogota: Litografia ARCO; 1980. p. 97–100.
5. Tabbara KF, El-Sheikh HF, Vera-Cristo CL. Complications of laser in situ keratomileusis (LASIK). Eur J Ophthalmol. 2003;13:139–46.
6. Schallhorn SC, Amesbury EC, Tanzer DJ. Avoidance, recognition, and management of LASIK complications. Am J Ophthalmol. 2006;141:733–9.
7. Farjo AA, Sugar A, Schallhorn SC, et al. Femtosecond lasers for LASIK flap creation: a report by the American Academy of Ophthalmology. Ophthalmology. 2013;120:e5–e20.
8. Gimbel HV, Iskander NG, Peters NT, Anderson Penno EE. Prevention and management of microkeratome-related laser in situ keratomileusis complications. J Refract Surg. 2000;16(suppl):S2–269.
9. Sridhar MS, Rao SK, Vajpayee RB, et al. Complications of laser in situ keratomileusis. Indian J Ophthalmol. 2002;50:265–82.
10. Gimbel HV, Penno EE, van Westernbrugge JA, Ferensowicz M, Furlong MT. Incidence and management of intraoperative and early postoperative complications in 1000 consecutive laser in situ keratomileusis cases. Ophthalmology. 1998;105:1839–48.
11. Yildirim R, Devranoglu K, Ozdamar A, Aras C, Ozkiris A, Ozkan S. Flap complications in our learning curve of laser in situ keratomileusis using the Hansatome microkeratome. Eur J Ophthalmol. 2001;11:328–32.
12. Baviera J. Dislocated flaps: how to solve free flaps with no marks or flap malposition. In: Alio JL, Azar DT, editors. Management of complications in refractive surgery. Berlin: Springer; 2008. p. 21–7.
13. Hovanesian JA, Maloney RK. Treating astigmatism after a free laser in situ keratomileusis cap by rotating the cap. J Cataract Refract Surg. 2005;31:1870–6.
14. Rubin ML. Optics for clinicians. Gainesville, FL: Triad Scientific; 1971. p. 179–81.