Lumbar Interbody Fusion

Pearls and Techniques

Editor-in-Chief
Satish Rudrappa

NSSA

Thieme

NSSA INDIA

Thieme

Lumbar Interbody Fusion

Pearls and Techniques

Editor-in-Chief

Satish Rudrappa, MCh (Neurosurgery), FASS (USA), FRCS (Glasgow)
Director,
Sakra Institute of Neurosciences,
Head,
Department of Spine Surgery,
Sakra World Hospital,
Bangalore, Karnataka, India

Editorial Board

Ramachandran Govindasamy, MS (Ortho), DNB (Ortho)
Department of Spine Surgery,
Sakra Institute of Neurosciences,
Bangalore, Karnataka, India

Veeramani Preethish-Kumar, MRCP (UK), MD-PhD (ICMR Fellow)
Department of Spine Surgery,
Sakra Institute of Neurosciences,
Bangalore, Karnataka, India

Thieme
Delhi • Stuttgart • New York • Rio de Janeiro

Publishing Director: Ritu Sharma
Development Editor: Dr Nidhi Srivastava
Director-Editorial Services: Rachna Sinha
Project Manager: Sambhavi Shah, Nidhi Chopra
Vice President, Sales and Marketing: Arun Kumar Majji
Managing Director & CEO: Ajit Kohli

Thieme Medical and Scientific Publishers Private Limited.
A - 12, Second Floor, Sector - 2, Noida - 201 301,
Uttar Pradesh, India, +911204556600
Email: customerservice@thieme.in
www.thieme.in

Cover design: Thieme Publishing Group
Typesetting by RECTO Graphics, India

Printed in India by Nutech Print Services

5 4 3 2 1

ISBN: 978-93-88257-54-1
eISBN: 978-93-88257-55-8

Important note: Medicine is an ever-changing science undergoing continual development. Research and clinical experience are continually expanding our knowledge, in particular, our knowledge of proper treatment and drug therapy. Insofar as this book mentions any dosage or application, readers may rest assured that the authors, editors, and publishers have made every effort to ensure that such references are in accordance with **the state of knowledge at the time of production of the book.**

Nevertheless, this does not involve, imply, or express any guarantee or responsibility on the part of the publishers in respect to any dosage instructions and forms of applications stated in the book. **Every user is requested to examine carefully** the manufacturers' leaflets accompanying each drug and to check, if necessary, in consultation with a physician or specialist, whether the dosage schedules mentioned therein or the contraindications stated by the manufacturers differ from the statements made in the present book. Such examination is particularly important with drugs that are either rarely used or have been newly released in the market. Every dosage schedule or every form of application used is entirely at the user's own risk and responsibility. The authors and publishers request every user to report to the publishers any discrepancies or inaccuracies noticed. If errors in this work are found after publication, errata will be posted at www.thieme.com on the product description page.

Some of the product names, patents, and registered designs referred to in this book are in fact registered trademarks or proprietary names even though specific reference to this fact is not always made in the text. Therefore, the appearance of a name without designation as proprietary is not to be construed as a representation by the publisher that it is in the public domain.

Contents

Foreword



I am pleased to know that Dr. Satish Rudrappa, President of Neuro Spinal Surgeon's Association, has compiled a monograph on lumbar interbody fusion (LIF) to be released on the occasion of 2019 Neuro Spinal Surgeon's Conference. It is pleasing to note that in this era of minimally invasive spinal surgeries, the editor-in-chief has chosen to compile the history, evolution, and recent developments in the field of LIF, which clearly indicates its enormous importance in the field.

The most important aspect in treating spinal disorders is the maintenance of sagittal balance as mentioned by the editor in his column. It is indeed the anchor for a good functioning spine.

The editor has taken pains to invite contributors from across the world to cover each and every aspect of the topic so that the monograph looks almost like a book in the archives. Right from the good old posterior LIF that I practiced and propagated, to the writing on minimally invasive surgery (MIS), and endoscopic transforaminal LIF, the editor has made humungous efforts to compile these methodically. The editor-in-chief has also vividly described the techniques of MIS which all aspiring young spinal surgeons will find educative.

Oblique or anterior techniques are re-emerging, especially in surgeries to treat deformities. But the general feeling that everything can be approached by posterior routes has kept these approaches dormant. However, the re-emergence of these techniques and their utilities have been well-described by the contributors who have written the chapters. For a person like me, these chapters hold extreme importance from the point of view of recent developments in LIF techniques.

In the current world, there is a big hue and cry over the implants being overused. The message from the chapter on "Implants and Biologics in Lumbar Interbody Fusion" should be perceived intelligently.

Dr. Satish Rudrappa is not only a hardworking and intelligent neuro spinal surgeon, but also highly research-oriented in the field of medicine. I am confident that this monograph will prove to be instructive and a useful bible for all the readers. I would also like to keep a personal copy in my library.

Dr. P. S. Ramani
Founder President, Neuro Spinal Surgeons Association, India

Note from the Editor-in-Chief

It is fascinating to see how lumbar spine surgery has evolved over centuries, from external manipulation to endoscopy guided minimally invasive surgical techniques in the recent decade. The most common pathology affecting the lumbar spine is degeneration.

There are different ways a surgeon thinks, in approaching a lumbar pathology. The ultimate aim for any surgeon in such a situation is to provide adequate decompression and reconstruct the spine to its normal anatomy as much as possible. Achieving sagittal balance of lumbosacral spine is the key for mobility in humans. Lumbar interbody fusion (LIF) is indispensable in restoring this balance in the diseased spine.

There are different approaches available for performing an LIF and the choice of surgery is influenced by multiple factors like patient's clinical presentation, X-ray, and MRI profile. Making the appropriate choice of surgery has a definite impact on postoperative long-term outcomes.

The purpose of this book is to discuss the advantages and shortcomings of each LIF procedure and the need to pick the right approach or a combination of approaches for the ultimate benefit of the patient. I sincerely believe and wish that the readers, especially spine surgeons, will benefit from this monograph.

Satish Rudrappa, MCh (Neurosurgery), FASS (USA), FRCS (Glasgow)

Contributors

Achal Gupta
Lilavati Hospital and Research Centre,
Mumbai, Maharashtra, India

Alvin Y. Chan
Department of Neurological Surgery,
University of California,
San Francisco, CA, USA

Andrew K. Chan
Department of Neurological Surgery,
University of California,
San Francisco, CA, USA

Apurva Prasad
Lilavati Hospital and Research Centre,
Mumbai, Maharashtra, India

Arjun Dhawale, MS (Ortho), DNB (Ortho), MRCS (Edinburgh)
Consultant Spine Surgeon,
Department of Orthopedics and Spine Surgery,
Sir HN Reliance Foundation Hospital and Research Center,
Mumbai, Maharashtra, India

Arvind Bhave, MS (Ortho), IPTM, EICOE,
Fellow Spinal Injuries (Japan)
Spine Surgeon and Spine Endoscopist,
Deenanath Mangeshkar Hospital,
Pune, Maharashtra, India

Dheeraj Masapu, MD, DM (Neuroanesthesia)
Associate Consultant,
Sakra Institute of Neurosciences,
Bengaluru, Karnataka, India

J. K. B. C. Parthiban, MCh (Neurosurgery), FNS (Japan)
Senior Consultant,
Department of Neurosurgery,
Kovai Medical Center and Hospital,
Coimbatore, Tamil Nadu, India

Joshua J. Rivera
Department of Neurological Surgery,
University of California,
San Francisco, CA, USA

Justin M. Lee
Department of Neurological Surgery,
University of California,
San Francisco, CA, USA

Karl Janich, MD
Medical College of Wisconsin,
Milwaukee, WI, USA

Komal Prasad Chandrachari, MS, DNB, MCh (Neurosurgery), PGDHHM, PGDMLE, MNAMS
Senior Consultant Neurosurgeon and Spinal Surgeon,
Narayana Hrudayalaya Institute of Neurosciences,
Mazumdar Shaw Medical Center, NH Health City,
Bengaluru, Karnataka, India

Kshitij Chaudhary, MS (Ortho), DNB (Ortho), FACS
Consultant Spine Surgeon,
Department of Orthopaedics and Spine Surgery,
Sir HN Reliance Foundation Hospital and Research Center,
Mumbai, Maharashtra, India

Kumar Abhinav
Lilavati Hospital and Research Centre,
Mumbai, Maharashtra, India

Naresh K. Pagidimarry, MS
Barat Academy of Spine Endoscopy (BASE),
Hyderabad, India

Peng Yin
Department of Orthopaedics,
Beijing Chao-Yang Hospital, China Capital Medical University,
Beijing, China

Praveen V. Mummaneni, MD
Department of Neurological Surgery,
Joan O'Reilly Endowed Chair,
Professor and Vice-Chairman
University of California,
San Francisco, USA

P. S. Ramani, MBBS, MS, MSc Neurosurgery (UK), DSc, FNAMS (National Academy)
Senior Consultant
Neuro and Spinal Surgeon,
Lilavati Hospital and Research Centre,
Mumbai, Maharashtra, India

Ramachandran Govindasamy, MS (Ortho), DNB (Ortho)
Spine Consultant,
Department of Spine Surgery,
Sakra Institute of Neurosciences,
Bangalore, Karnataka, India

Said G. Osman, MD, FRCS (Edinburgh) (Ortho)
Sky Spine Endoscopy Institute,
Frederick, MD, USA

Sajesh Menon, MS (Ortho), DNB (Ortho), MCh
Clinical Professor and Head,
Department of Neurosurgery,
Amrita Institute of Medical Science,
Kochi, Kerala, India

Satish Rudrappa, MCh (Neurosurgery), FASS (USA), FRCS (Glasgow)
Director, Sakra Institute of Neurosciences,
Head, Department of Spine Surgery,
Sakra World Hospital,
Bengaluru, Karnataka, India

S. N. Kurpad, MD-PhD
Sanford J Larson Professor and Chairman,
Department of Neurosurgery,
Medical College of Wisconsin,
Milwaukee, WI, USA

Sukumar Sura, MCh (Neurosurgery), FRCS (Edinburgh)
Department of Neurosurgery,
Yashoda Hospitals, Hyderabad, India

Sumeet Sasane
Lilavati Hospital and Research Centre,
Mumbai, Mumbai, Maharashtra, India

T. V. Ramakrishna, MS (Ortho), FISS & FISD (Japan)
Department of Neurosurgery,
Yashoda Hospitals, Hyderabad, India

Veeramani Preethish-Kumar, MRCP (UK), MD-PhD (ICMR Fellow)
Associate Consultant,
Academic and Research Head,
Sakra Institute of Neurosciences,
Bengaluru, Karnataka, India

Vivian P. Le
Department of Neurological Surgery,
University of California,
San Francisco, USA

Yaoshen Zhang
Department of Orthopaedics,
Beijing Chao-Yang Hospital, China Capital Medical University,
Beijing, China

Yiqi Zhang
Department of Orthopaedics,
Beijing Chao-Yang Hospital, China Capital Medical University,
Beijing, China

Yong Hai, MD-PhD
Professor, Department of Orthopaedics,
Beijing Chao-Yang Hospital,
China Capital Medical University,
Beijing, China

Yu Liang, MD
Professor, Deputy Chief,
Director, Spine Division,
Department of Orthopaedics,
Ruijin Hospital, School of Medicine,
JiaoTong University, Shanghai, China

Chapter 1
History of Lumbar Interbody Fusion

1 History of Lumbar Interbody Fusion

P. S. Ramani, Sumeet Sasane, Apurva Prasad, Achal Gupta, Kumar Abhinav

Introduction

History is very important and an integral component of any man-made technological advancement, especially in the field of medicine. The history of treatment for any spinal disease follows the same path as any other medical illness dating to the beginning of human history. Indian and Egyptian texts reveal descriptions of spinal instability as early as ca. 1550 BC. Hippocrates (460–377 BC), the Greek physician, may have been a pioneer in describing spinal conditions in a scientific manner, and many physicians followed his teachings.[1,2] Hence, it is evident that the concept of "spine correction and stabilization" existed for centuries, but the way to do so was not clear until the late 19th century (**Fig. 1.1**). Today, in the modern era, numerous surgical techniques are available for the stabilization of the spine. After reviewing from a historical perspective, it will be apparent how dependent we remain upon the work of those who came before us so that we can write further on any new advances. However, many times new discoveries are serendipitous.



Fig. 1.1 Hippocrates.

Historical Background

The evolution of external spine-fixation devices was during the 15th and 16th century when physicians tried to understand the complex biomechanical mechanisms of the spine.[3,4] Later, the management paradigm shifted toward surgery because of the discovery of anesthesia and antisepsis in 1846 and 1867, respectively.[5] The first surgical attempt in spine was by Berthold Hadra,[6] a Prussia-based surgeon from Texas, in 1891. He attempted to stabilize an 8-month-old dislocated fracture of the sixth and seventh cervical vertebrae. He incised from occiput to first thoracic vertebra and tried to fuse the adjacent spinous processes using silver wires in a figure-of-8 fashion (**Fig. 1.2**). But he was modest enough to give the credit to Wilkins, who had successfully done a similar procedure before him in treating a dislocated fracture of the dorsolumbar region. There was a substantial rise in tuberculosis (TB) leading to a high prevalence of Pott's spine and spinal deformities in the 18th and 19th century. This leads to the discovery of internal stabilization of spine starting from cervical spine and gradually finding its way to the lumbar spine. Following Hadra, Chipault performed the same wiring technique for internal fixation of five Pott's spine cases by 1895.[7] In 1908, Fritz Lange[8] tied tin-plated steel rods to the spine with wires. However, he gave up on using steel due to corrosion issues.

The Concept of Spinal Fusion Using "On-Lay" Bone Graft

Fred Albee[9] and Russel Hibbs[10] from New York laid the scientific foundation for lumbar fusion through their technique of posterior on-lay bone grafting for patients with TB spine. They published their results independently in 1911. Later, surgeons adapted the same technique for the correction of scoliosis or spinal fractures.

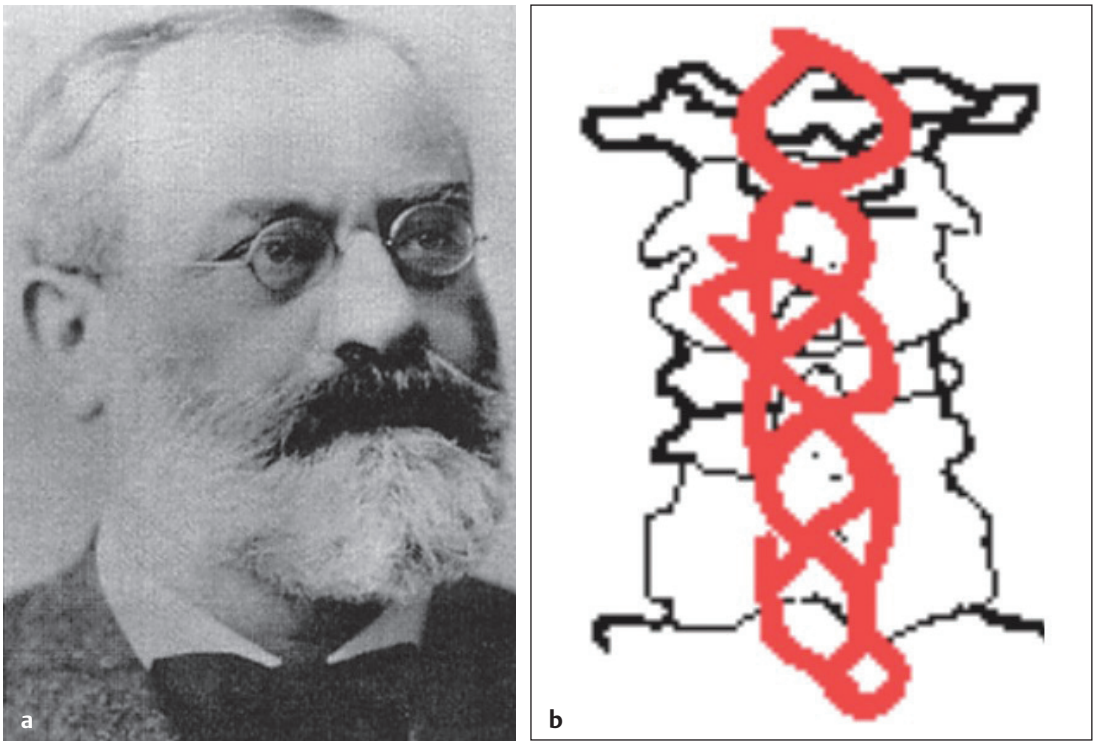

Fig. 1.2 Berthold Ernest Hadra **(a)**, a physician and surgeon from Prussia who revolutionized spinal surgical techniques and the figure-of-8 interspinous wiring **(b)**.

This technique was further elaborated by other surgeons adding iliac crest or tibial bone grafts. As a matter of interest, within a short period of time, Albee preceded Hibbs in using grafts. He compared the strength of bone grafting over internal metal splints and found high rates of failure of rods and wires due to direct absorption and bone atrophy.

Posterior approach gained popularity and small case series on spine instrumentations started coming up. Campbell in 1920 first described trisacral fusion through autografting from iliac crest to the transverse processes of L4/L5 vertebrae.[11] This is the first documented "lumbosacral fusion" technique, which laid the foundation for successive posterior spinal instrumentation techniques. However, non-union due to corrosion of implants was a major concern. In 1933, Ghormley[12] used iliac crest grafts on the transverse processes for fusion and following this, it became the procedure of choice and gained popularity among contemporary surgeons.

In 1936, Venable and Stuck introduced Vitallium[13] (an alloy of cobalt, chromium, and molybdenum) that was inert and resistant to corrosion, overcoming the major issue with steel. In the late 1940s, King adapted Hibbs' technique by adding facet screw.[14–16] He was the first to use vertebral screw fixation and thereby immediately obtaining good rigid fixation, avoiding prolonged brace immobilization. But the short screws in the facets resulted in high incidence of pseudoarthrosis.[17] Despite several modifications to the technique, the incidence of pseudoarthrosis remained an ever-unsolvable problem in surgeries with on-lay bone grafting.

Evolution of "Interbody" Fusion Procedures of the Lumbar Spine

The Anterior Lumbar Interbody Fusion

The anterior approaches emerged in the 1930s (by Burns and Capener) mainly for treating spondylolisthesis. In 1933, Burns performed

anterior fusion, through an anterior transperitoneal approach by left paramedian incision, drilling a hole in the fifth lumbar vertebra and filling it with autograft. This procedure had good postoperative outcome but the recovery was prolonged. This anterior approach claimed to have key advantages.[18,19] It provides a direct midline view of the disc space and efficient preparation, leading to high fusion rates. It also facilitates maximization of the implant size and surface area and, thereby, aggressive correction of lordosis and foraminal height. Nonetheless, Mobbs et al[20] reported approach-related complications such as retrograde ejaculation and visceral and vascular injury. Moreover, anterior lumbar interbody fusion (ALIF) is not suitable at L2–L4 vertebral level (retroperitoneal retraction and risk of superior mesenteric artery thrombosis).

Posterior Lumbar Interbody Fusion

Since anterior approaches were associated with significant morbidity and prolonged recovery time, Briggs and Milligan in 1944 revolutionized fusion surgeries and described a novel technique, combining a posterior approach with interbody fusion technique. It involved wide laminectomy, facetectomy, discectomy, and usage of a round bone peg for stability. This principle was later adapted by Cloward[21] and he described the first posterior lumbar interbody fusion (PLIF) procedure with few modifications. He used multiple small tricortical grafts from the posterior iliac crest and allografts from cadaver, thus further improving fusion rates up to 85%.[21] However, this was not gaining popularity, as it was very difficult and not every surgeon could achieve his expertise. Several surgeons adapted their own techniques to make PLIF simpler and more attractive, so that maximum number of surgeons can use it.

Lin from Philadelphia was one of the spinal surgeons who successfully advocated PLIF using only cancellous bone from the posterior iliac crest.[22] He described the principle of "Unipour Concept." His concepts were also based on "Flagpole concept" as described by a biomechanical engineer named Evans.[23] It states that a flagpole should be rooted to the ground by three wires so that it can remain stable. In a spine scenario, the three wires are anterior longitudinal ligament, facet joints laterally, and the interspinous and supraspinous ligaments. The lumbar interbody fusion (LIF) represents the flagpole here. However, there were shortcomings with Lin's construct as it was too soft and caused early settlement with foraminal stenosis. Despite all these modifications, standalone posterior interbody fusion fell out of favor due to technical difficulties, potential serious complications, and low fusion rates.

Ramani's construct contains a mixture of cancellous portion of bone (auto and allo) to make a 5-mm layer at the base and at the sides.[24] He added two tricortical bone graft from his own bone bank in the center and two bicortical bone graft from the posterior iliac crest, which improved the fusion rates (**Fig. 1.3**).

Understanding Spinal Biomechanics—Emergence of the Pedicle Screw

Up till this stage, following any spinal fusion procedure, the patients had to be immobilized for a prolonged period; at least 6 weeks depending on the extent of instability. They will be cautiously mobilized with rigid lumbar brace, with or without hip lock, and will be allowed to sit up only after another 2 weeks. After spending several months postoperatively, walking would be initiated but by then, most of the patients will lose the zeal to work anymore.

Boucher described placing screws in the pedicle in 1959, but it was Roy Camille from France in 1970 who described sagittal screw placement across three columns: from articular process through the pedicle into the body and combined them with a plate construct.[16] Harrington combined pedicle screws with his rod system, which was originally developed for treating scoliosis (**Fig. 1.4**). He felt that standalone spinal instrumentation without fusion often resulted in implant failure owing to a race between development of fusion and failing implant material. The insight that instrumentation and bone grafting should be combined was a major step ahead in spine surgery.[25,26]